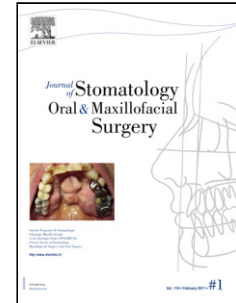


Journal Pre-proof

Management of mandibular condylar fractures in patients with atrophic edentulous mandibles

Matteo Brucoli MD DDS Paolo Boffano MD Irene Romeo MD Chiara Corio MD Arnaldo Benech MD DDS Muhammad Ruslin MD DDS PhD Tymour Forouzanfar MD DDS PhD Tanía Rodríguez-Santamarta MD DDS Juan Carlos de Vicente MD DDS PhD Marko Tarle MD Emil Dediol MD PhD Petia Pechalova MD DDS PhD Nikolai Pavlov MD DDS Hristo Daskalov MD DDS Iva Doykova MD DDS Kadri Kelemith DDS Tiia Tamme MD PhD Andrey Kopchak MD DDS PhD Ievgen Shumynskyi MD DDS Pierre Corre MD PhD Helios Bertin MD PhD Maeva Bourry MD Pierre Guyonvarc'h MD Tadej Dovšak MD PhD David Vozlič MD Anže Birk MD Boban Aničić MD DDS Vitomir S Konstantinovic DDS MD MSc PhD Thomas Starch Jensen MD PhD



PII: S2468-7855(19)30249-6

DOI: <https://doi.org/doi:10.1016/j.jormas.2019.10.004>

Reference: JORMAS 757

To appear in: *Journal of Stomatology oral and Maxillofacial Surgery*

Received Date: 1 October 2019

Accepted Date: 14 October 2019

Please cite this article as: Brucoli M, Boffano P, Romeo I, Corio C, Benech A, Ruslin M, Forouzanfar T, Rodríguez-Santamarta T, de Vicente JC, Tarle M, Dediol E, Pechalova P, Pavlov N, Daskalov H, Doykova I, Kelemith K, Tamme T, Kopchak A, Shumynskyi I, Corre P, Bertin H, Bourry M, Guyonvarc'h P, Dovšak T, Vozlič D, Birk A, Aničić B, Konstantinovic VS, Jensen TS, Management of mandibular condylar fractures in patients with atrophic edentulous mandibles, *Journal of Stomatology oral and Maxillofacial Surgery* (2019), doi: <https://doi.org/10.1016/j.jormas.2019.10.004>

This is a PDF file of an article that has undergone enhancements after acceptance, such as the addition of a cover page and metadata, and formatting for readability, but it is not yet the definitive version of record. This version will undergo additional copyediting, typesetting and review before it is published in its final form, but we are providing this version to give early visibility of the article. Please note that, during the production process, errors may be discovered which could affect the content, and all legal disclaimers that apply to the journal pertain.

© 2019 Published by Elsevier.

Management of mandibular condylar fractures in patients with atrophic edentulous mandibles.

Matteo Brucoli MD DDS,¹ Paolo Boffano MD,¹ Irene Romeo MD,¹ Chiara Corio MD,¹ Arnaldo Benech MD DDS,¹ Muhammad Ruslin MD DDS PhD,² Tymour Forouzanfar MD DDS PhD,³ Tanía Rodríguez-Santamarta MD DDS,⁴ Juan Carlos de Vicente MD DDS PhD,⁴ Marko Tarle MD,⁵ Emil Dediol MD PhD,⁵ Petia Pechalova MD DDS PhD,⁶ Nikolai Pavlov MD DDS,⁷ Hristo Daskalov MD DDS,⁶ Iva Doykova MD DDS,⁸ Kadri Kelemith DDS,⁹ Tiia Tamme MD PhD,¹⁰ Andrey Kopchak MD DDS PhD,¹¹ Ievgen Shumynskyi MD DDS,¹² Pierre Corre MD PhD,¹³ Helios Bertin MD PhD,¹³ Maeva Bourry MD,¹³ Pierre Guyonvarc'h MD,¹³ Tadej Dovšak MD PhD,¹⁴ David Vozlič MD,¹⁴ Anže Birk MD,¹⁴ Boban Aničić MD DDS,¹⁵ Vitomir S. Konstantinovic DDS MD MSc PhD,¹⁵ Thomas Starch-Jensen MD PhD.¹⁶

¹ Division of Maxillofacial Surgery, University Hospital "Maggiore della Carità", University of Eastern Piedmont, Novara, Italy

² Department of Oral and Maxillofacial Surgery, Hasanuddin University, Makassar, Indonesia

³ Department of Oral and Maxillofacial Surgery/Oral Pathology, VU University Medical Center, Amsterdam, The Netherlands

⁴ Servicio de Cirugía Maxilofacial, Hospital Universitario Central de Asturias, Oviedo, Spain

⁵ Department of Maxillofacial Surgery, University Hospital Dubrava, Zagreb, Croatia

⁶ Department of Oral surgery, Faculty of Dental Medicine, Medical University, Plovdiv, Bulgaria

⁷ Private practice of oral surgery, Plovdiv, Bulgaria

⁸ Department of maxillofacial surgery, Faculty of Dental Medicine, Medical University, Plovdiv, Bulgaria

⁹ Department of maxillo-facial surgery, North Estonia Medical Centre Foundation, Tallinn, Estonia.

¹⁰ Faculty of Medicine, University of Tartu, Tartu, Estonia

¹¹ Bogomolets National Medical University, Stomatological medical center, Kyiv, Ukraine.

¹² Bogomolets National Medical University, Kyiv City Clinical Emergency Hospital, Kyiv, Ukraine

¹³ Division of Maxillofacial Surgery, Chu de Nantes, Nantes, France

¹⁴ Department of *Maxillofacial* and Oral Surgery of the University Medical Centre, Ljubljana, Slovenia

¹⁵ Department of Maxillofacial surgery, School of Dental Medicine, University of Belgrade, Serbia

¹⁶ Department of Oral and Maxillofacial Surgery, Aalborg University Hospital, Aalborg, Denmark

Address correspondence and reprint requests to Dr Paolo Boffano: Division of Maxillofacial Surgery, University Hospital "Maggiore della Carità", University of Eastern Piedmont, Novara, Italy
E-mail address: paolo.boffano@gmail.com

Disclosure: *The authors have no financial interest to declare in relation to the content of this article.*

No funding

ABSTRACT:

INTRODUCTION

Treatment of condylar fractures in patients with atrophic edentulous mandibles is a peculiar field that has been little considered in the literature. The aim of the study was to assess the demographic and clinical variables as well as management and outcome of mandibular condylar fractures in edentulous patients with atrophic mandibles that were treated at several European departments of oral and maxillofacial surgery.

METHODS

The data of all patients with fractures of the atrophic edentulous mandible from the involved maxillofacial surgical units across Europe between January 1, 2008, and December 31, 2017. Only patients that were diagnosed with condylar fractures of the edentulous atrophic mandible were included.

RESULTS

A total of 52 patients met the inclusion criteria and were included in the study: 79% of patients reported one or more comorbidities. 34 unilateral neck or subcondylar fractures, 9 bilateral neck or subcondylar condylar fractures, 7 unilateral head condylar fractures, and 2 bilateral head condylar fractures were diagnosed. No treatment was performed in 37 cases, whereas in 4 patients a closed treatment was decided, and 11 patients underwent open reduction and internal fixation. Outcome was considered to be satisfying in 48 patients, with no complications.

CONCLUSIONS

The golden rule still remains that the diagnosis of a subcondylar or neck fracture in an edentulous patient should constitute an indication for open reduction and internal fixation. However, an appropriate choice of management options has to be individualized on a case by case basis, also depending on the patient consent.

Keywords: condylar fracture; management; surgery; edentulous; atrophic mandible.

INTRODUCTION

Management of mandibular condylar fractures represents a controversial issue in maxillofacial trauma. In particular, treatment of condylar fractures in edentulous patients with atrophic mandibles is a peculiar field that has been little considered in the literature.¹⁻²¹

Minimally displaced condylar fractures in the edentulous atrophic mandible are generally treated conservatively and minor occlusal changes are corrected by fabrication of new prostheses. Moreover, small deviations in mandibular motion and aesthetics are commonly of minor importance for elderly edentulous patients. However, open reduction and rigid fixation of displaced and unstable mandibular condylar fractures in the edentulous atrophic mandible is frequently necessary to maintain the posterior vertical height of the mandibular ramus. Moreover, the provoked loss of vertical mandibular ramus height due to condylar fractures may cause altered jaw mechanics with either deviation toward the fractured side or, in the case of bilateral fractures, open bite deformity.²²⁻²⁴

Therefore, open reduction and rigid fixation has been suggested for displaced mandibular condylar (neck and subcondylar) fractures in edentulous patients with loss of vertical ramus height.²²⁻²⁴

Previously, only few studies have evaluated the treatment outcome after the management of mandibular condylar fractures in edentulous patients. However, small patient samples, different treatment modalities and short-term observation period diminish the possibility of providing evidence-based treatment guidelines of mandibular condylar fractures in edentulous patients. Consequently, several European centers that had already shown research experience in maxillofacial trauma decided to collaborate on a multicenter research project about the management of mandibular condylar fractures in edentulous patients, in order to obtain a wide study population and to reduce bias.

The aim of the study was to assess the demographic and clinical variables as well as management and outcome of mandibular condylar fractures in edentulous patients with atrophic mandibles treated at several European departments of oral and maxillofacial surgery.

METHODS

This study was conducted at several European departments of oral and maxillofacial surgery: Division of Maxillofacial Surgery, University of Eastern Piedmont (Novara, Italy); Department of Maxillofacial Surgery, University Hospital Dubrava (Zagreb, Croatia); Clinic of Maxillofacial Surgery, School of Dentistry, University of Belgrade (Belgrade, Serbia); Department of Oral surgery, Faculty of Dental medicine, Medical University (Plovdiv, Bulgaria); Department for Oral and Maxillofacial Surgery, Bogomolets National Medical University (Kiev, Ukraine); Service de Stomatologie et

Chirurgie Maxillo-faciale, CHU de Nantes (Nantes, France); Department of Oral and Maxillofacial Surgery, Aalborg University Hospital (Aalborg, Denmark); Department of Maxillofacial Surgery, North Estonia Medical Centre Foundation (Tallinn, Estonia); Department of *Maxillofacial* and Oral Surgery of the University Medical Centre (Ljubljana, Slovenia); Maxillofacial Department, Hospital Universitario Central de Asturias (Oviedo, Spain).

The data of all patients with fractures of the atrophic edentulous mandible from the involved maxillofacial surgical units across Europe between January 1, 2008, and December 31, 2017.

Only patients that were diagnosed with condylar fractures of the edentulous atrophic mandible were included.

The following data were recorded for each patient: gender; age; comorbidities; etiology; degree of atrophy of the mandible; type of condylar fracture (unilateral or bilateral; head, neck or subcondylar), according to AO classification of condylar fractures; type of management (observation, closed treatment, open reduction and internal fixation); length of hospital stay; presence and type of complications.

The following categories of the cause of injury were considered: fall, motor vehicle accident (MVA), assault, sport injury, work injury, and other cause.

The degree of atrophy of the mandibles was categorized according to Luhr et al⁵: bone height from 16 to 20 mm was classified as Class I, from 11 to 15 mm as Class II, and less than 10 mm as Class III atrophy.

As for management, the observation option included a soft diet for 30 days and progressive rehabilitation exercises to restore mandibular excursions to retrieve mouth opening, lateral excursion and protrusion for 30 days. Closed treatment involved a period of maxillomandibular fixation followed progressive functional therapy with rubber bands.

Patient characteristics were analyzed using descriptive statistics. Statistical analysis was used to search for associations among multiple variables. Statistical significance was determined using the X² test or, if the sample sizes were too small, the Fisher exact test. Statistical significance was set at .05. We followed the Helsinki Declaration guidelines, according to local laws. The study was exempt from requiring institutional review board approval as a retrospective study, according to a local institution.

RESULTS

A total of 52 patients (18 male and 34 female patients) met the inclusion criteria and were included in the study.

The mean age of the study population was 75.7 years (median, 78 years; standard deviation, 12.1 years; range, 42 to 98 years).

On the whole, 41 patients (79%) reported one or more comorbidities, the most frequent being hypertension (26), followed by diabetes (9), heart rhythm disease (8), and dementia (3).

As for aetiology, the most frequent cause of injury was fall with 40 patients, followed by other causes (4 patients), assaults (3 patients), MVAs (3 patients), and work accident (2 patients)(Figure 1).

On the whole, 14 patients' mandibles were classified as class I according to Luhr, 34 as class II, and 4 as class III (Figure 2).

Within the study population, 34 unilateral neck or subcondylar fractures, 9 bilateral neck or subcondylar condylar fractures, 7 unilateral head condylar fractures, and 2 bilateral head condylar fractures were diagnosed.

Figure 3 depicts the distribution of condylar fractures according to Luhr classes.

Observation was performed in 37 cases, whereas in 4 patients a closed treatment was decided, and 11 patients underwent open reduction and internal fixation.

Figure 4 depicts the distribution of performed management according to condylar fracture types. Outcome was considered to be satisfying in 48 patients, with no complications. Two patients died during hospital stay for heart comorbidities. Complications were observed in 2 cases (TMJ pain, limited mouth opening): all two patients were assigned to the observation option.

Mean length of hospital stay was 2.3 days (range, 0 – 18) in patients that underwent observation, whereas mean stay was 5.5 days in patients that underwent closed or open treatment (range, 2 – 11).

No significantly statistical association was found between the considered variables.

DISCUSSION

Management of mandibular condylar fractures in edentulous patients with atrophic mandibles is a controversial topic, which has not received much attention in the literature.¹⁻²⁴

The mean age of the study population of the present study testifies that age (and the associated health issues) still represents an important factor to be considered, as well as the high prevalence of comorbidities.

Furthermore, the presence of dentures, and the economic possibilities for new dentures are further elements to be considered.

Therefore, it seems that no strict rules of indications can be applied to edentulous patients with mandibular condylar fractures, but clinical decision has to be taken, in agreement with the patient, on a case by case basis.

As for the etiopathogenesis of condylar fractures in edentulous patients, our study population interestingly shows that the distribution of condylar fracture subtypes does not change according to Luhr classes of atrophy. Therefore, the decrease of height and thickness of atrophic mandibles does not seem to contribute to different types of condylar fractures.²²⁻²⁴

As for treatment, head fractures were either treated by ORIF or they underwent simple observation. This choice may be due to the different experiences of the single centers about the possibility of surgical treatment for head fractures. Most centers preferred to manage head fractures by a conservative attitude with observation.

Instead, the choice of the most appropriate treatment for neck or subcondylar fractures is much more difficult. In fact, a conservative attitude represented the preferred option for neck and subcondylar fractures too, probably due to the health conditions of the patients or because of the opposition to surgery by some old patients. Furthermore, the degree of displacement or dislocation of the fractured condyle may have also had an important role in influencing the surgeon's decision. For example, in some involved centers, if the condyle was not dislocated, surgeons just suggested observation or closed treatment. Otherwise, if a decreased height of mandible was observed, ORIF was the preferred option.²²⁻²⁴ When a treatment was decided, the closed treatment option was applied in selected cases, for example when the patients had dentures that could be used to this aim. Otherwise, an open reduction and internal fixation was performed as shown in Figures 5, 6, and 7.

Outcome was considered to be satisfying in 48 patients, with no complications. Complications were observed in 2 cases (TMJ pain, limited mouth opening): all two patients were assigned to the observation option.

Therefore, an appropriate selection of patients and the relative indications seems to be the crucial feature for a successful management of condylar fractures in edentulous patients.

CONCLUSIONS

The golden rule still remains that the diagnosis of a subcondylar or neck fracture in an edentulous patient with the atrophic mandible should constitute an indication for open reduction and internal fixation. However, the theory often has to face several practical management problems and difficulties, associated with poor medical conditions and old age of such patients. Therefore, an

appropriate choice of management options has to be individualized on a case by case basis, also depending on the patient consent.

REFERENCES:

1. Wittwer G, Adeyemo WL, Turhani D, Ploder O. Treatment of atrophic mandibular fractures based on the degree of atrophy--experience with different plating systems: a retrospective study. *J Oral Maxillofac Surg.* 2006 Feb;64(2):230-4.
2. Ellis E 3rd, Price C. Treatment protocol for fractures of the atrophic mandible. *J Oral Maxillofac Surg.* 2008 Mar;66(3):421-35.
3. Clayman L, Rossi E. Fixation of atrophic edentulous mandible fractures by bone plating at the inferior border. *J Oral Maxillofac Surg.* 2012 Apr;70(4):883-9.
4. Castro-Núñez J, Shelton JM, Snyder S, Sickels JV. Virtual Surgical Planning for the Management of Severe Atrophic Mandible Fractures. *Craniomaxillofac Trauma Reconstr.* 2018 Jun;11(2):150-156.
5. Luhr HG, Reidick T, Merten HA. Results of treatment of fractures of the atrophic edentulous mandible by compression plating: a retrospective evaluation of 84 consecutive cases. *J Oral Maxillofac Surg.* 1996 Mar;54(3):250-4
6. Nasser M, Fedorowicz Z, Ebadifar A. Management of the fractured edentulous atrophic mandible. *Cochrane Database Syst Rev.* 2007 Jan 24;(1):CD006087
7. Flores-Hidalgo A, Altay MA, Atencio IC, Manlove AE, Schneider KM, Baur DA, Quereshy FA. Management of fractures of the atrophic mandible: a case series. *Oral Surg Oral Med Oral Pathol Oral Radiol.* 2015 Jun;119(6):619-27.
8. Ruslin M, Brucoli M, Boffano P, Benech A, Dediol E, Uglešić V, Kovačić Ž, Vesnaver A, Konstantinović VS, Petrović M, Stephens J, Kanzaria A, Bhatti N, Holmes S, Pechalova PF, Bakardjiev AG, Malanchuk VA, Kopchak AV, Galteland P, Mjøen E, Skjelbred P, Bertin H, Corre P, Løes S, Lekven N, Laverick S, Gordon P, Tamme T, Akermann S, Karagozoglu KH, Kommers SC, de Visscher JG, Forouzanfar T. Motor vehicle accidents-related maxillofacial injuries: a multicentre and prospective study. *Oral Surg Oral Med Oral Pathol Oral Radiol.* 2018 Dec 13. pii: S2212-4403(18)31306-3. doi: 10.1016/j.oooo.2018.12.009. [Epub ahead of print]
9. Brucoli M, Boffano P, Broccardo E, Benech A, Corre P, Bertin H, Pechalova P, Pavlov N, Petrov P, Tamme T, Kopchak A, Hresko A, Shuminsky E, Dediol E, Tarle M, Konstantinovic VS, Petrovic M, Holmes S, Karagozoglu KH, Forouzanfar T. The "European zygomatic

- fracture" research project: The epidemiological results from a multicenter European collaboration. *J Craniomaxillofac Surg*. 2019 Apr;47(4):616-621.
10. Brucoli M, Boffano P, Pezzana A, Benech A, Corre P, Bertin H, Pechalova P, Pavlov N, Petrov P, Tamme T, Kopchak A, Romanova A, Shuminsky E, Dediol E, Tarle M, Konstantinovic VS, Jelovac D, Karagozoglu KH, Forouzanfar T. The "European Mandibular Angle" Research Project: The Epidemiologic Results From a Multicenter European Collaboration. *J Oral Maxillofac Surg*. 2019 Apr;77(4):791.e1-791.e7.
 11. Brucoli M, Boccafoschi F, Boffano P, Broccardo E, Benech A. The Anatomage Table and the placement of titanium mesh for the management of orbital floor fractures. *Oral Surg Oral Med Oral Pathol Oral Radiol*. 2018 Oct;126(4):317-321.
 12. Giarda M, Tavolaccini A, Arcuri F, Brucoli M, Benech A. Surgical approach to isolated bilateral orbital floor fractures. *Acta Otorhinolaryngol Ital*. 2015 Oct;35(5):362-4.
 13. Arcuri F, Brucoli M, Baragiotta N, Benech R, Ferrero S, Benech A. Analysis of complications following endoscopically assisted treatment of mandibular condylar fractures. *J Craniofac Surg*. 2012 May;23(3):e196-8.
 14. Brucoli M, Nestola DF, Baragiotta N, Boffano P, Benech A. Maxillofacial fractures: Epidemiological analysis of a single-center experience. *Otorinolaringologia* 2018; 68 (4): 132-137
 15. Brucoli M, Boffano P, Magnano M, Mistretta R, Benech R, Benech A. The management of a high-risk patient with edentulous mandibular fractures. *Otorinolaringologia* 2019; 68: 42-44
 16. Boffano P, Rocchia F, Zavattero E, Dediol E, Uglešić V, Kovačič Ž, Vesnaver A, Konstantinović VS, Petrović M, Stephens J, Kanzaria A, Bhatti N, Holmes S, Pechalova PF, Bakardjiev AG, Malanchuk VA, Kopchak AV, Galteland P, Mjølne E, Skjelbred P, Bertin H, Marion F, Guiol J, Corre P, Løes S, Lekven N, Laverick S, Gordon P, Tamme T, Akermann S, Karagozoglu KH, Kommers SC, Forouzanfar T. Assault-related maxillofacial injuries: the results from the European Maxillofacial Trauma (EURMAT) multicenter and prospective collaboration. *Oral Surg Oral Med Oral Pathol Oral Radiol*. 2015 Apr;119(4):385-91.
 17. Boffano P, Benech R, Gallesio C, Arcuri F, Benech A. Current opinions on surgical treatment of fractures of the condylar head. *Craniomaxillofac Trauma Reconstr*. 2014 Jun;7(2):92-100.

18. Boffano P, Corre P, Righi S. The Role of Intra-articular Surgery in the Management of Mandibular Condylar Head Fractures. *Atlas Oral Maxillofac Surg Clin North Am.* 2017 Mar;25(1):25-34.
19. Kommers SC, Boffano P, Forouzanfar T. Consensus or controversy? The classification and treatment decision-making by 491 maxillofacial surgeons from around the world in three cases of a unilateral mandibular condyle fracture. *J Craniomaxillofac Surg.* 2015 Dec;43(10):1952-60.
20. Brucoli M, Boffano P, Pezzana A, Benech A, Corre P, Bertin H, Pechalova P, Pavlov N, Petrov P, Tamme T, Kopchak A, Romanova A, Shuminsky E, Dediol E, Tarle M, Konstantinovic VS, Jelovac D, Karagozoglu KH, Forouzanfar T. The "European Mandibular Angle" research project: the analysis of complications after unilateral angle fractures. *Oral Surg Oral Med Oral Pathol Oral Radiol.* 2019 Jul;128(1):14-17.
21. Brucoli M, Boffano P, Bonaso M, Benech A. The management of a Y-shaped fracture of the mandibular ramus. *Otorinolaringologia* 2019 September;69(3):192-5
22. Weiss JP, Sawhney R. Update on mandibular condylar fracture management. *Curr Opin Otolaryngol Head Neck Surg.* 2016 Aug;24(4):273-8.
23. Berner T, Essig H, Schumann P, Blumer M, Lanzer M, Rücker M, Gander T. Closed versus open treatment of mandibular condylar process fractures: A meta-analysis of retrospective and prospective studies. *J Craniomaxillofac Surg.* 2015 Oct;43(8):1404-8.
24. Leiser Y, Peled M, Braun R, Abu-El Naaj I. Treatment of low subcondylar fractures--a 5-year retrospective study. *Int J Oral Maxillofac Surg.* 2013 Jun;42(6):716-20.

LEGENDS

Figure 1: etiological factors within the study population.

Figure 2: percentages of Luhr classes within the study population.

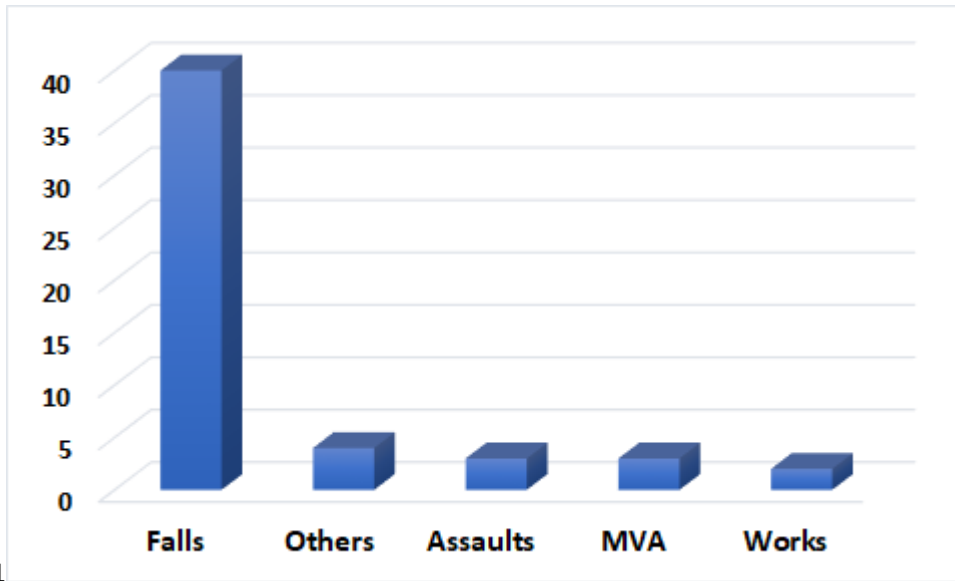
Figure 3: distribution of condylar fractures according to Luhr classes.

Figure 4: distribution of performed management according to condylar fracture types.

Figure 5: Female patient from Zagreb center, 70 years, reporting a dislocated left extracapsular condylar fracture following a fall (A, B). The patient presented altered jaw mechanics with deviation toward the fractured side. Past medical history included heart rhythm disease. The mandible was rated as Luhr Class II. The patient underwent open reduction and internal fixation, by the placement of a single 2.0 miniplate (C). Postoperative course was uneventful.

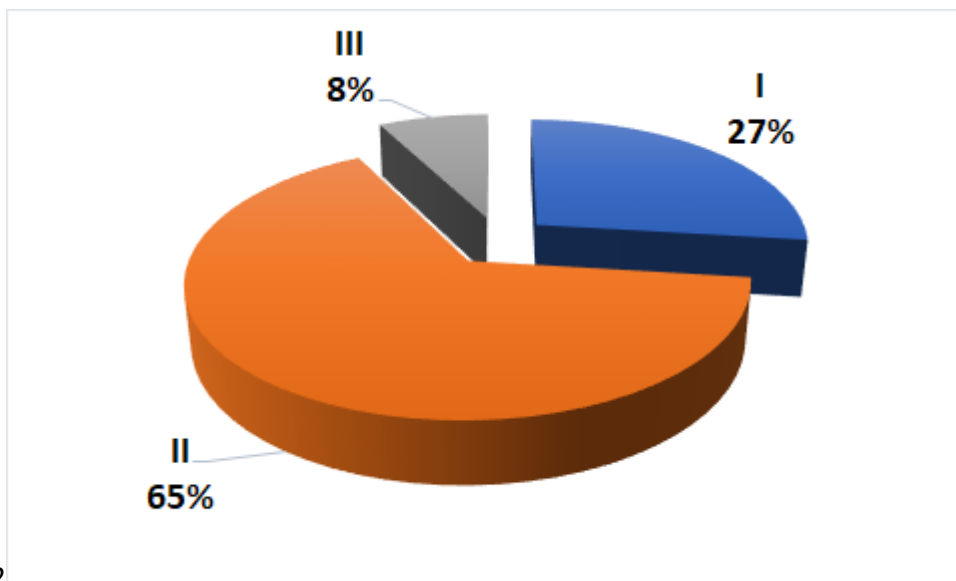
Figure 6: Female patient from Aalborg center, 76 years, reporting a dislocated right extracapsular condylar fracture following a fall (A, B, C). The patient presented difficulties in mouth opening with deviation toward the fractured side. Past medical history included hypertension and osteoporosis. The mandible was rated as Luhr Class II. The patient underwent open reduction and internal fixation, by the placement of a single condylar miniplate (D, E). Postoperative course was uneventful.

Figure 7: Male patient from Nantes center, 83 years, reporting a dislocated left extracapsular condylar fracture following a fall (A, B). The patient presented deviation toward the fractured side. Past medical history included cognitive disorders. The mandible was rated as Luhr Class I. The patient underwent open reduction and internal fixation, by the placement of two 2.0 miniplates (C, D, E). Postoperative course was uneventful.



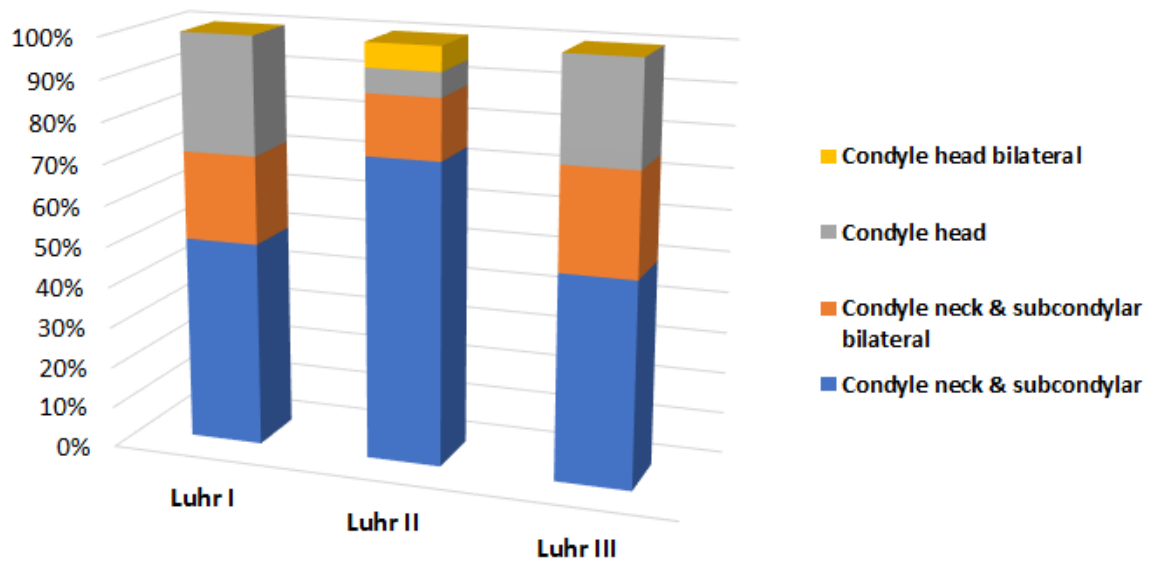
Figr-1

Journal Pre-proof



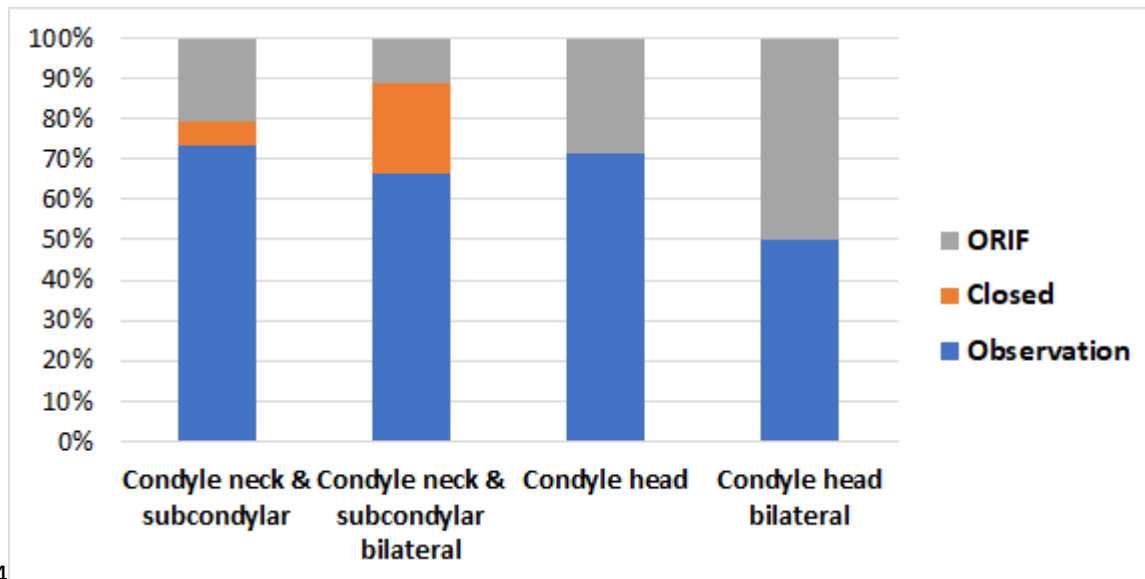
Figr-2

Journal Pre-proof



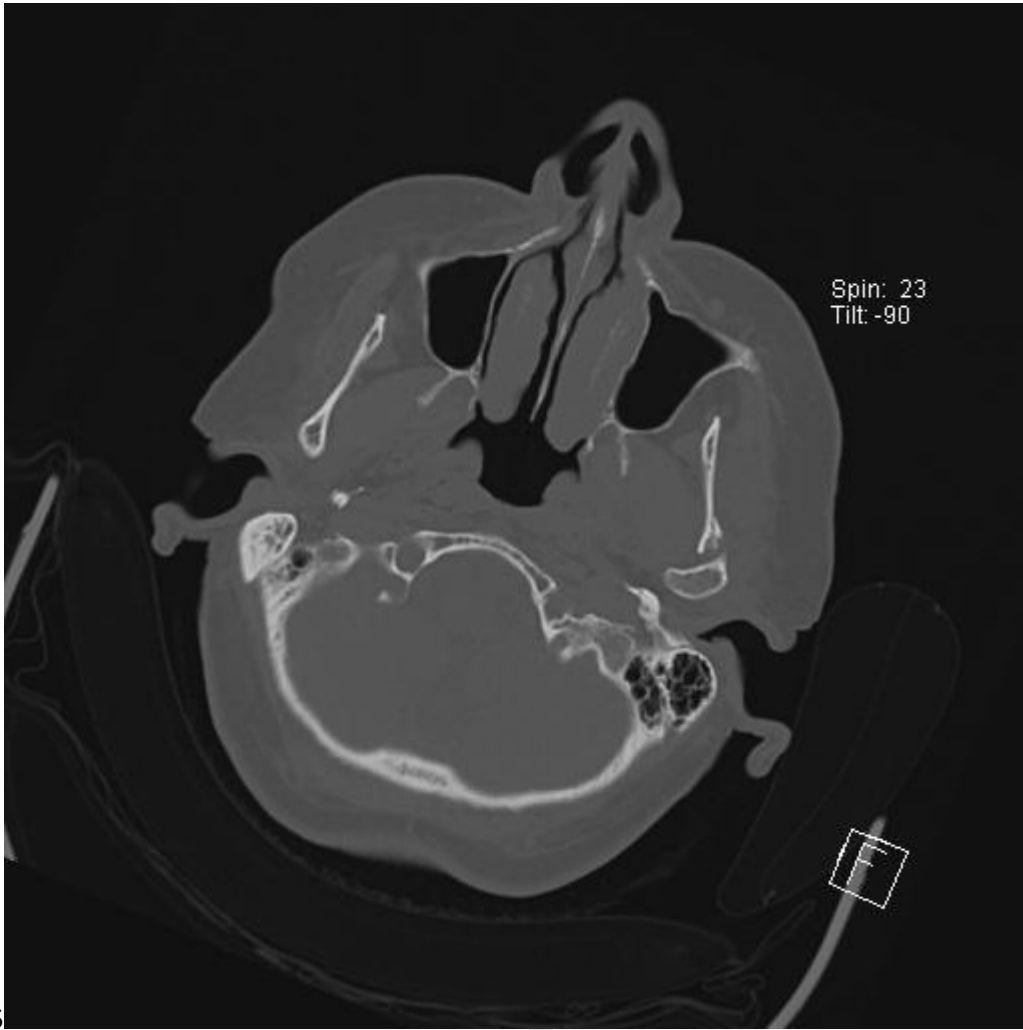
Figr-3

Journal Pre-proof



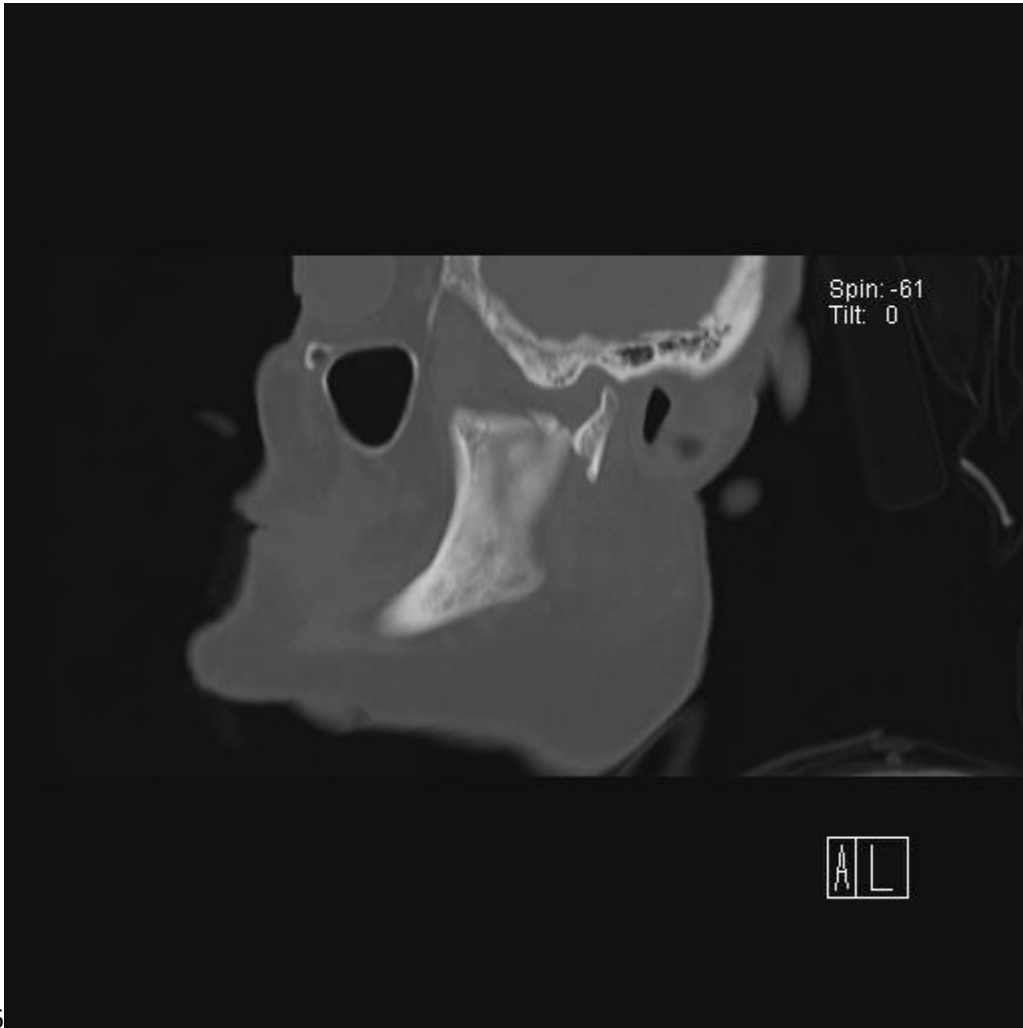
Figr-4

Journal Pre-proof



Figr-5

Journal



Figr-6

Journal

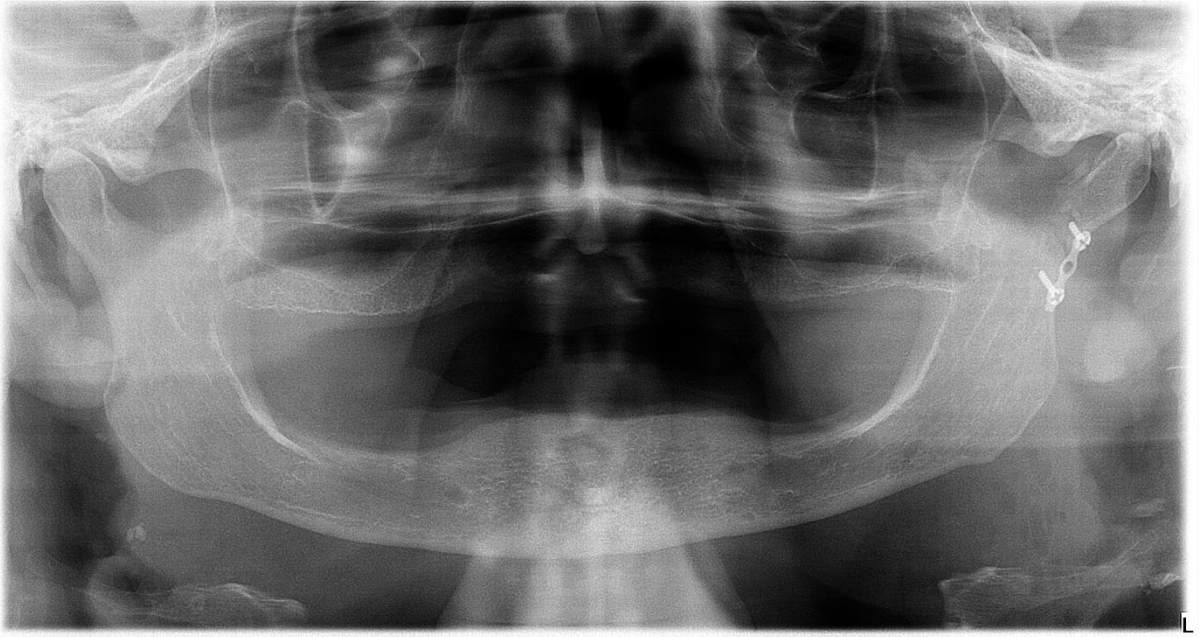


Fig-7

Journal Pre-proof

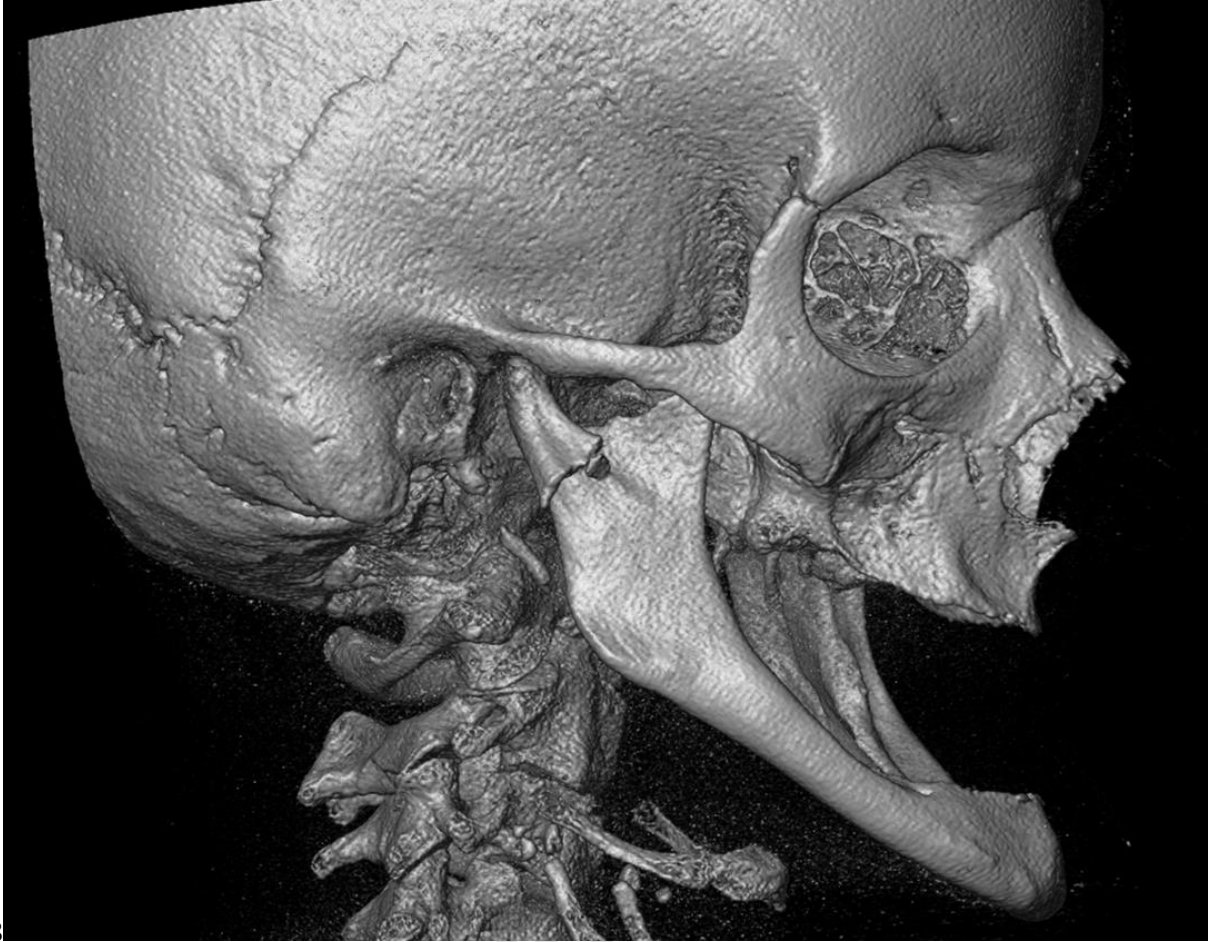

Fig-8

Journal Pre-proof

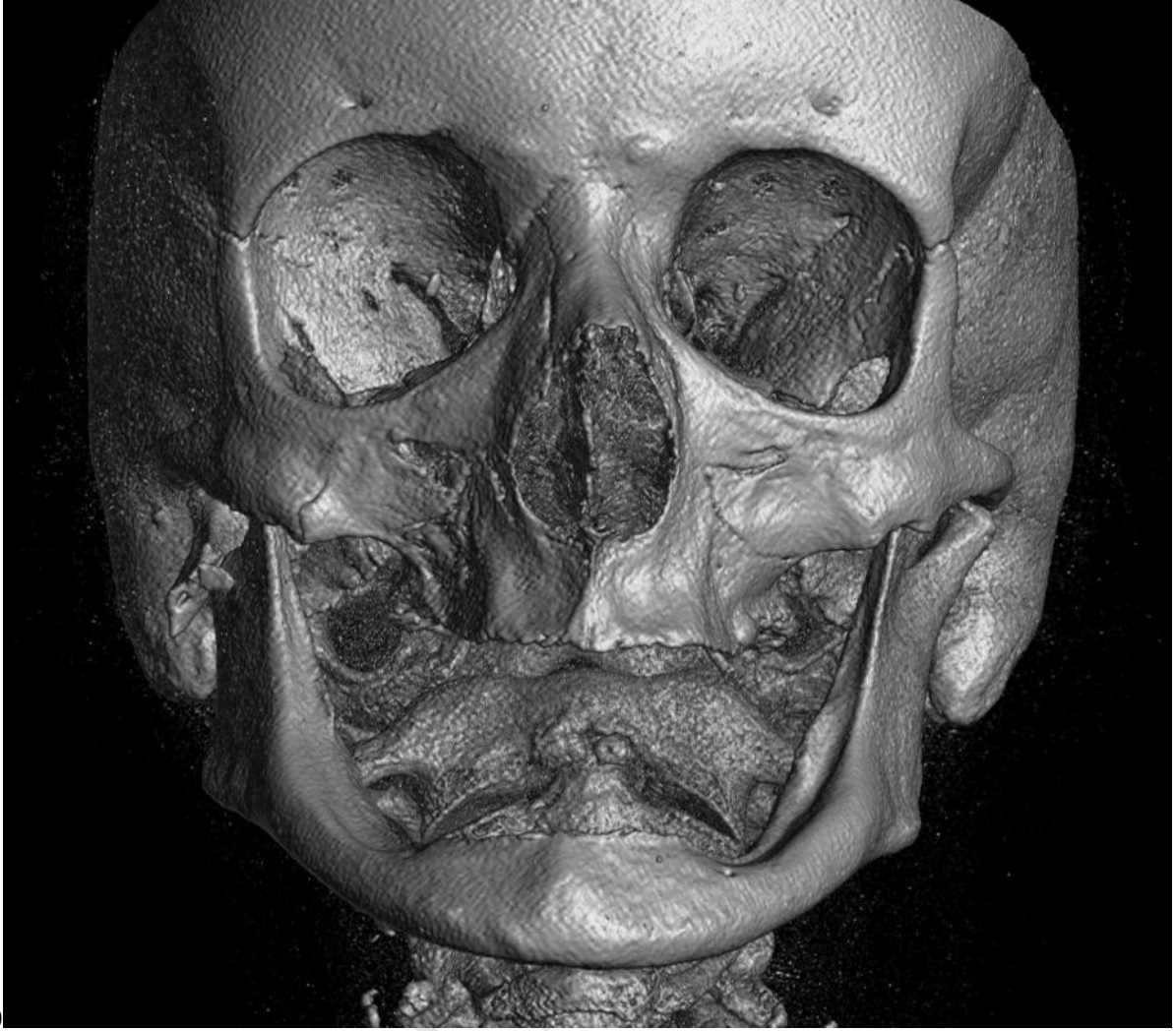
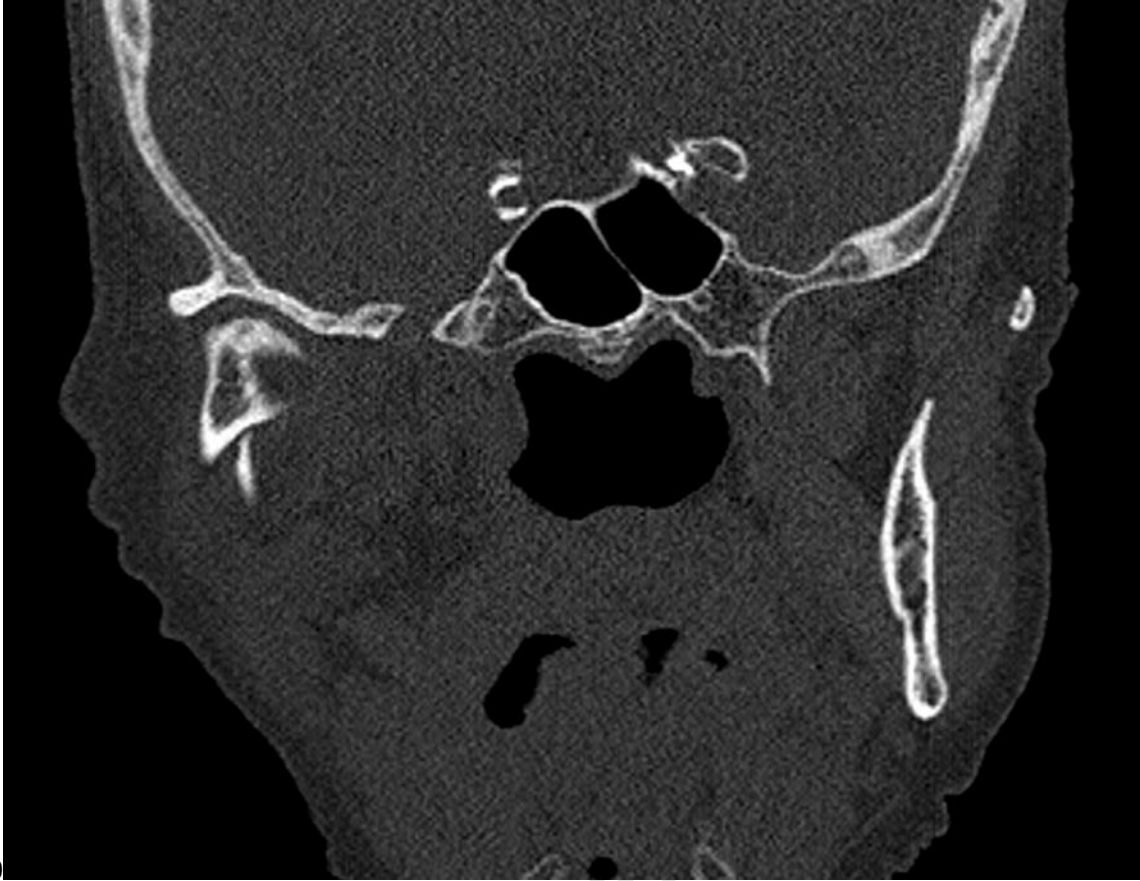
Fig-9

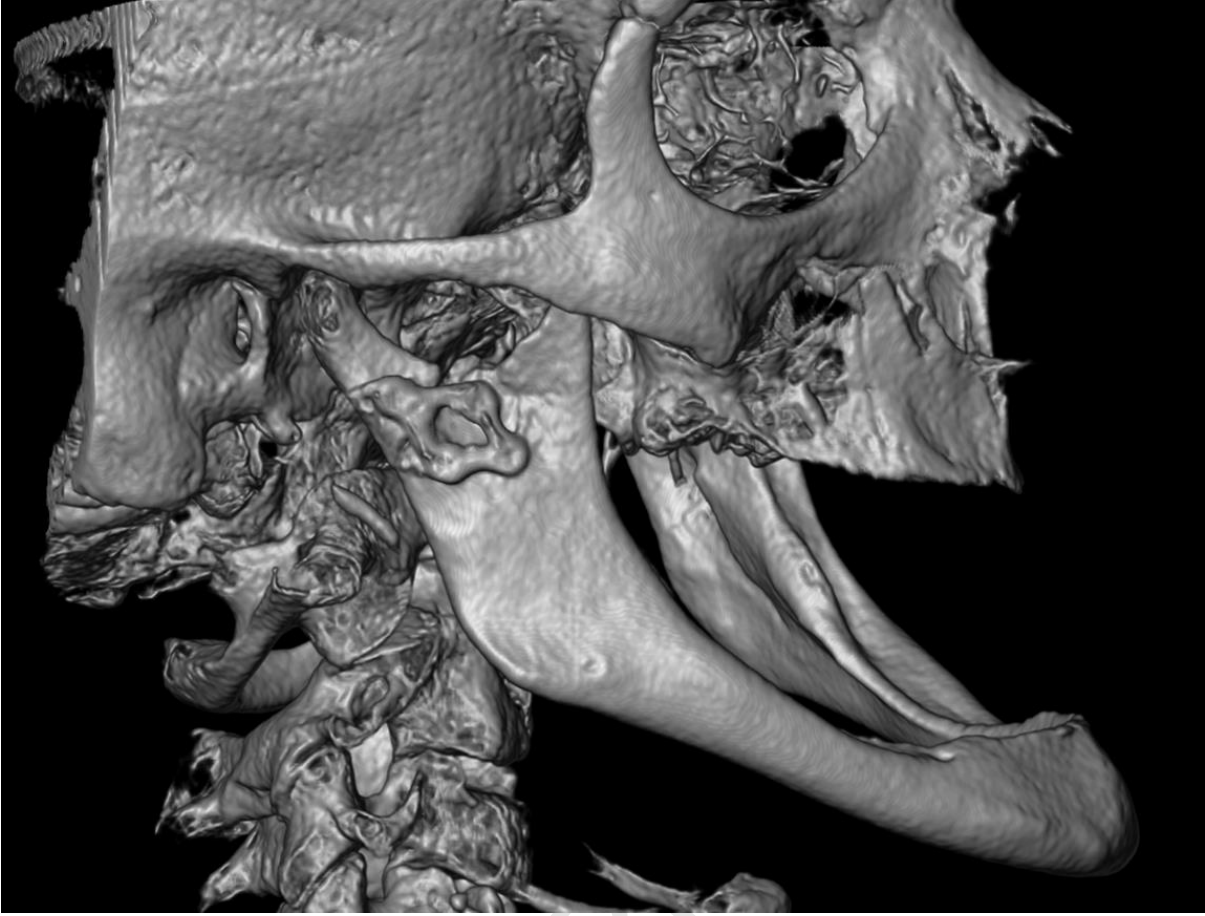
Journal



Figr-10

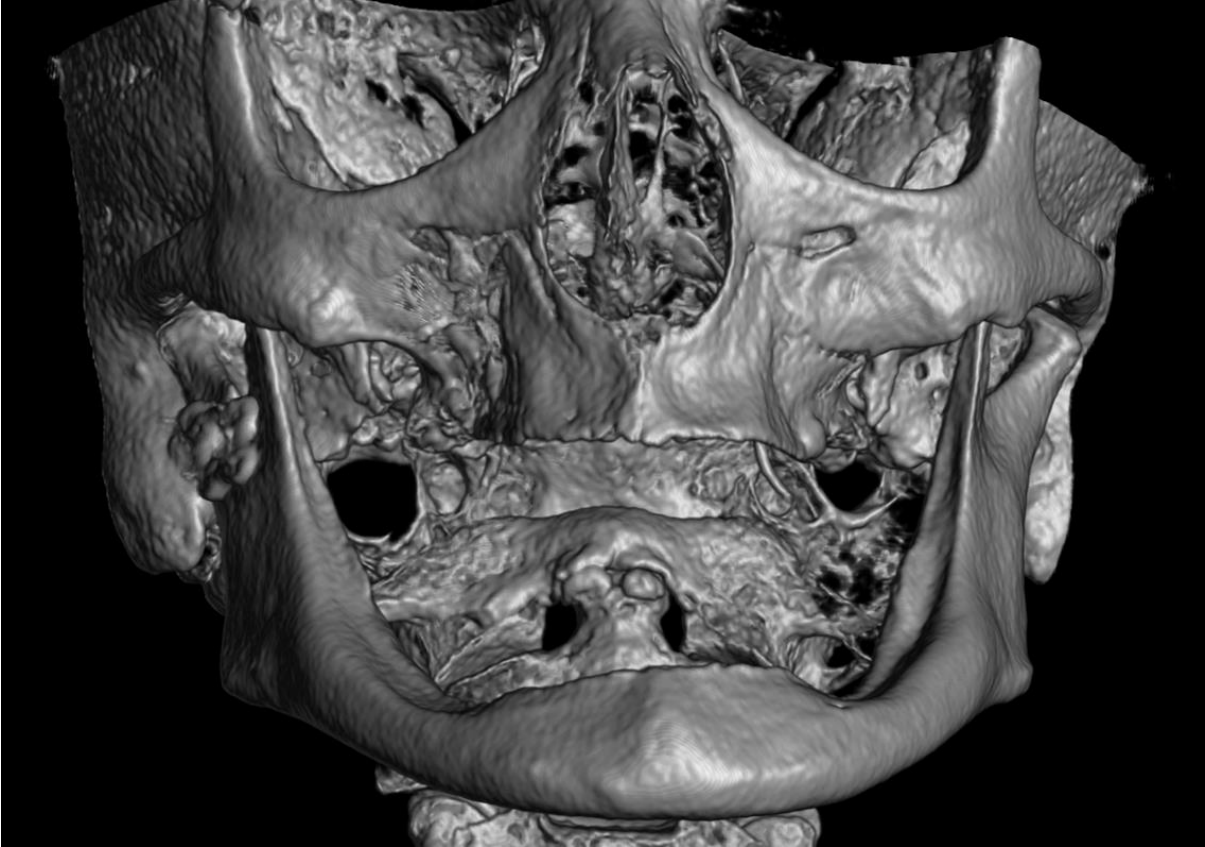
Journal Pre

Figr-11

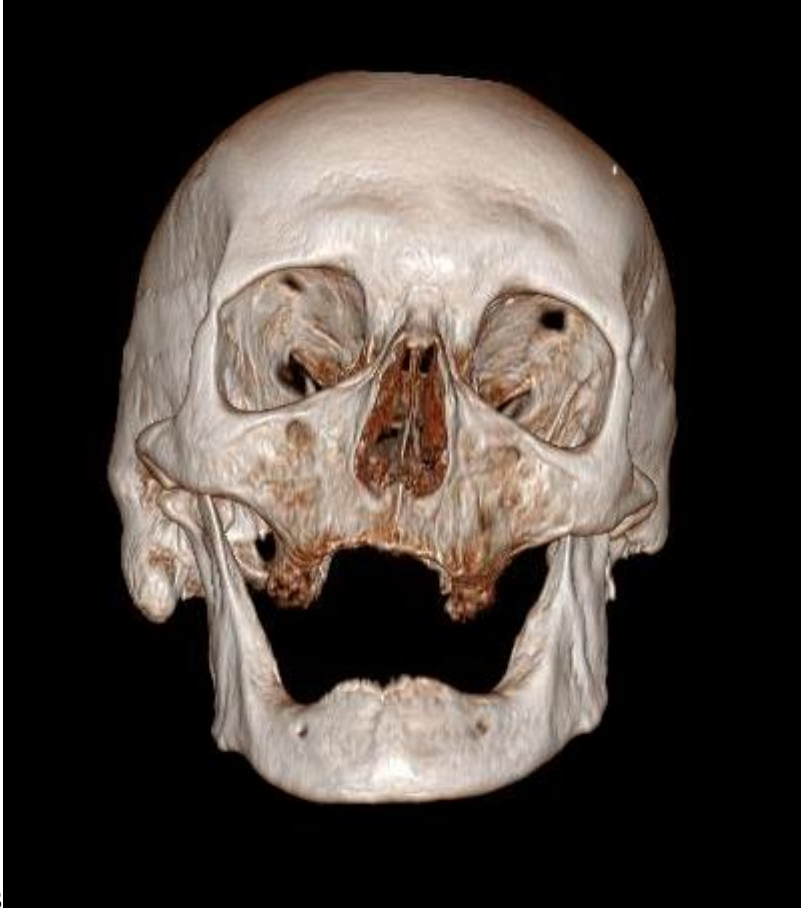

Journal Pre-proof

Figr-12



Journal Pre



Figr-13

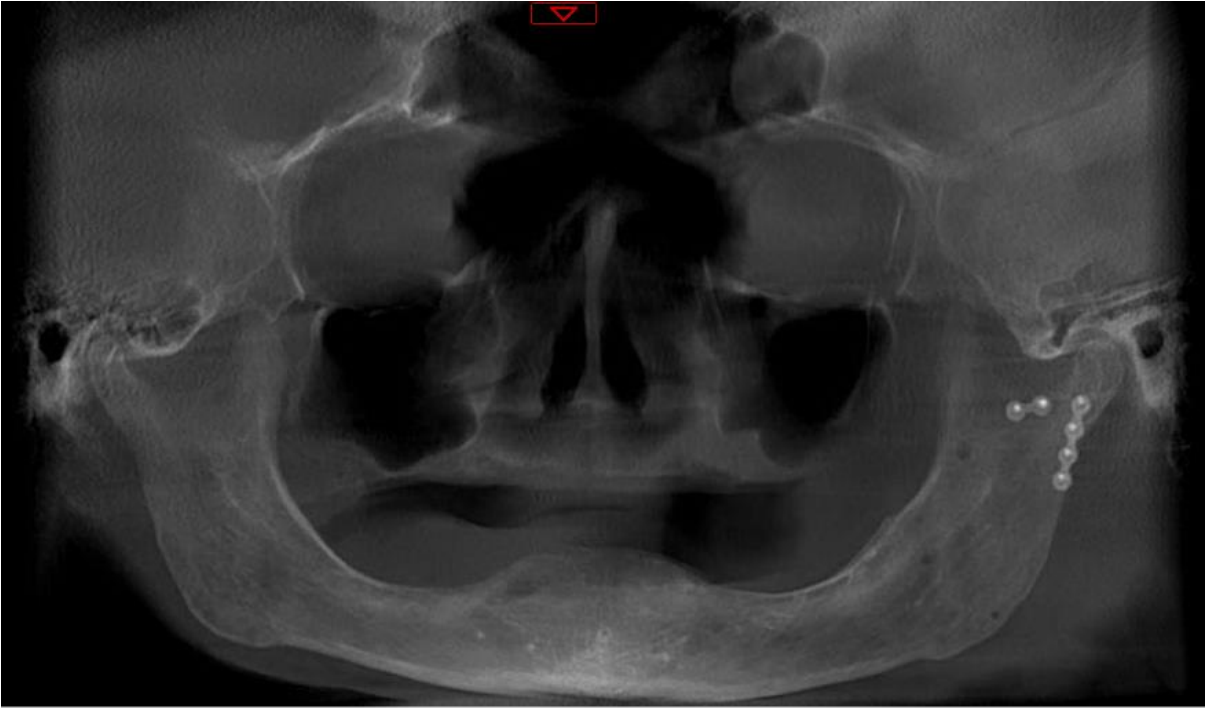
Journal Pre-proof

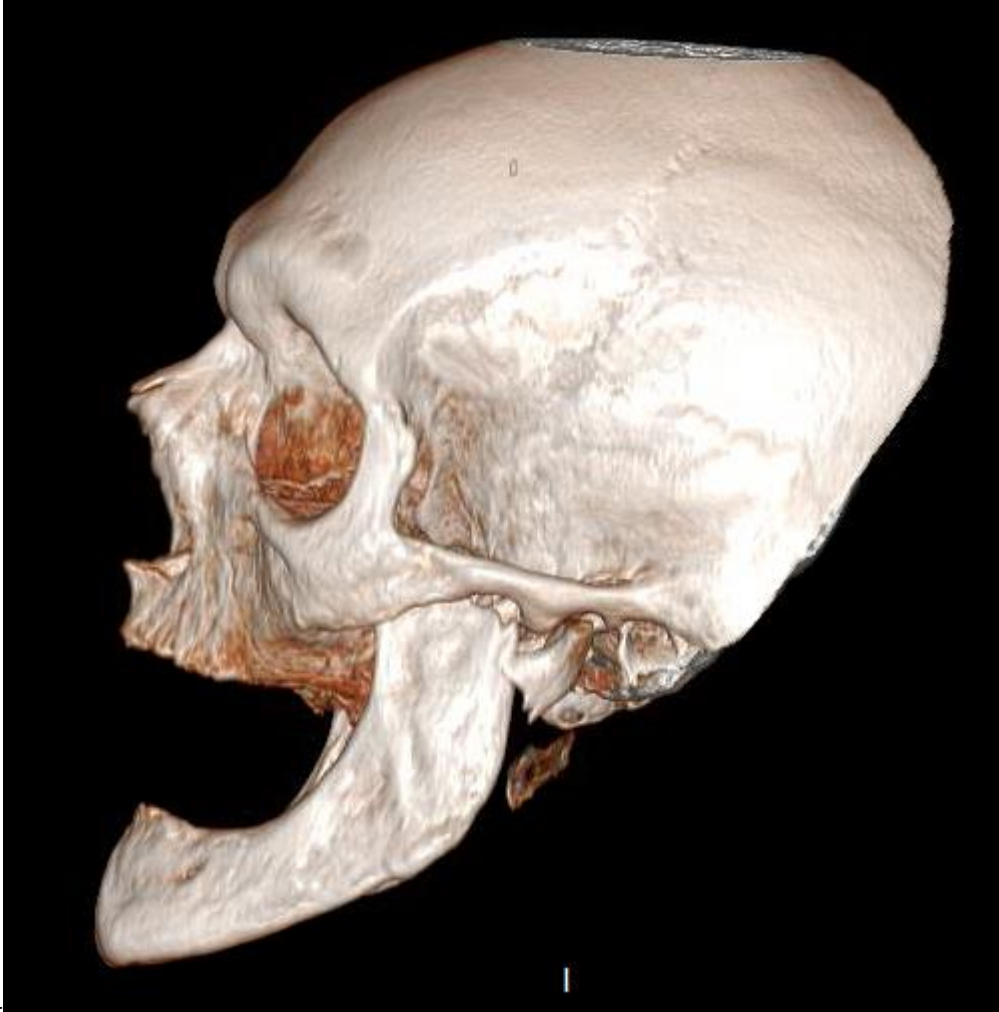

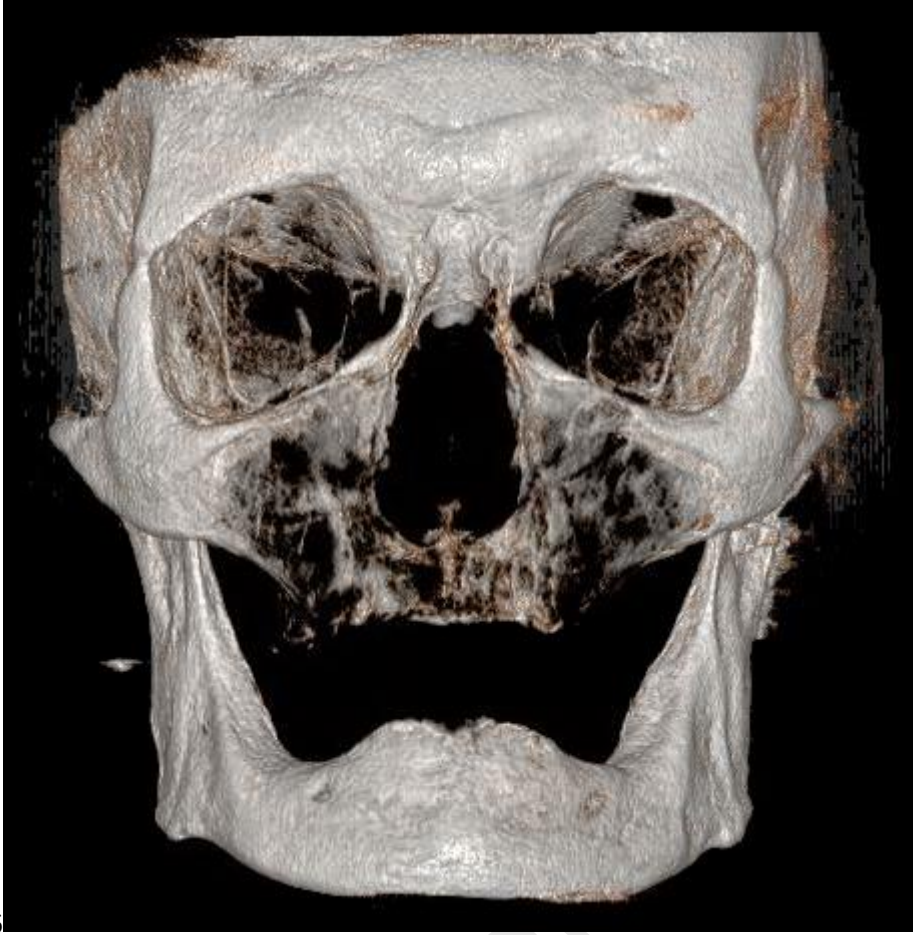Fig-14

Journal Pre-proof

Figr-15

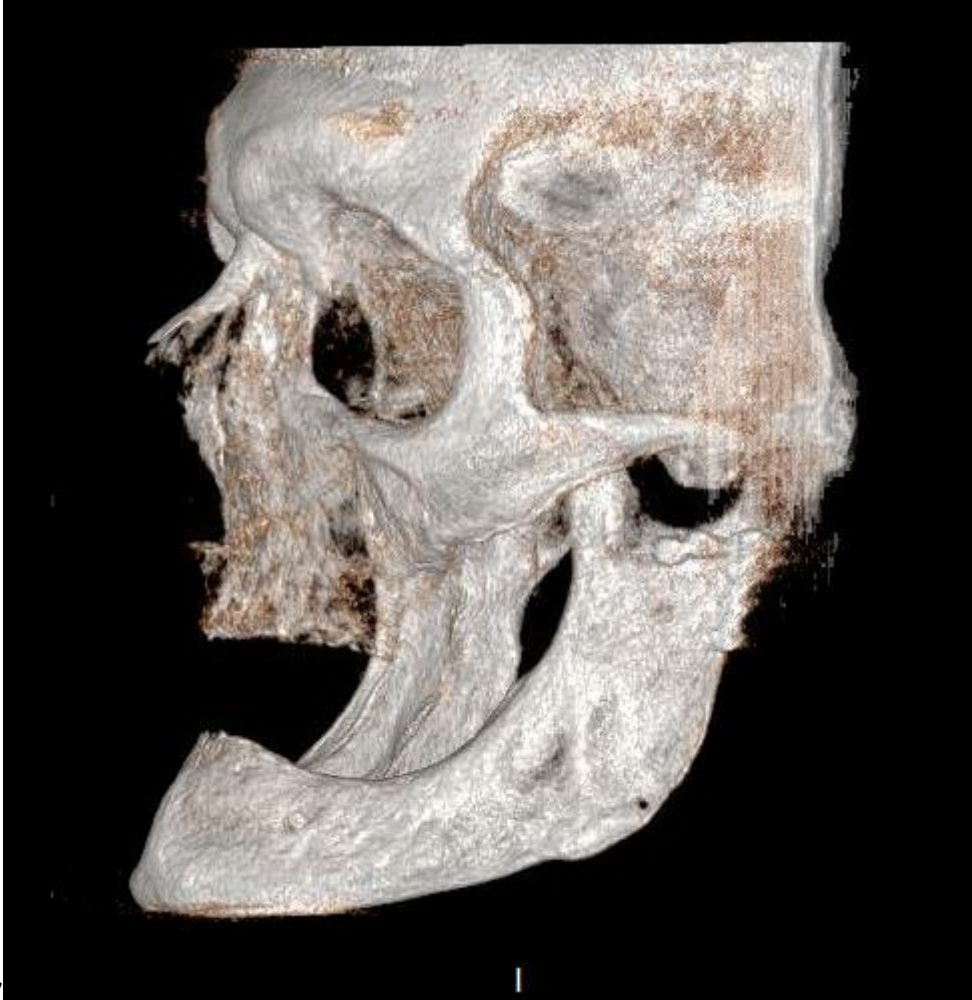

Journal Pre-proof



Figr-16

Journal Pre-proof



Figr-17

Journal Pre-proof