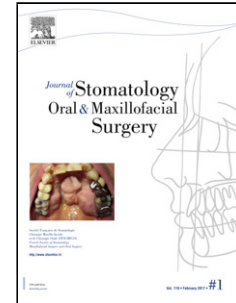


## Accepted Manuscript

Title: Amlodipine induced gingival overgrowth: a case report

Authors: Léonie Quenel MD, Pierre Keribin MD, Guillaume Giran MD, Marie-Hélène Tessier MD, Philippe Lesclous

PII: S2468-7855(19)30125-9  
DOI: <https://doi.org/10.1016/j.jormas.2019.04.014>  
Reference: JORMAS 696



To appear in:

Received date: 13 March 2019  
Accepted date: 24 April 2019

Please cite this article as: Quenel L, Keribin P, Giran G, Tessier M-Hélène, Lesclous P, Amlodipine induced gingival overgrowth: a case report, *Journal of Stomatology oral and Maxillofacial Surgery* (2018), <https://doi.org/10.1016/j.jormas.2019.04.014>

This is a PDF file of an unedited manuscript that has been accepted for publication. As a service to our customers we are providing this early version of the manuscript. The manuscript will undergo copyediting, typesetting, and review of the resulting proof before it is published in its final form. Please note that during the production process errors may be discovered which could affect the content, and all legal disclaimers that apply to the journal pertain.

**Title page**

Amlodipine induced gingival overgrowth: a case report

Léonie QUENEL, MD<sup>1</sup>, Pierre KERIBIN, MD<sup>2</sup>, Guillaume GIRAN, MD<sup>3</sup>, Marie-Hélène  
TESSIER, MD<sup>4</sup>, Philippe LESCLOUS<sup>5</sup>

1. MD, Registrar Oral Surgery, Nantes University, Nantes University Hospital, Nantes, France. leonie.quenel@outlook.fr
2. MD, Oral Surgeon, Nantes University; Nantes University Hospital; INSERM UMR-S 1229, RMeS; Nantes, France. pierre.keribin@gmail.com.
3. MD, Oral and Maxillofacial Surgeon, Department of Oral and Maxillofacial Surgery, Nantes University Hospital, Nantes, France. guillaume.giran@gmail.com
4. MD, Dermatologist, Department of Oral and Maxillofacial Surgery, Nantes University Hospital, Nantes, France. mh.tessier@wanadoo.fr
5. DDS, PhD, Oral Surgeon, Head of Department of Oral Surgery, Nantes University; Nantes University Hospital; INSERM UMR-S 1229, RMeS; Nantes, France. philippe.lesclous@univ-nantes.fr

**Corresponding author**

Pierre KERIBIN, Nantes Dental School; Nantes University Hospital; INSERM UMR-S 1229, RMeS; Nantes, France. pierre.keribin@gmail.com

**Title**

Amlodipine induced gingival overgrowth: a case report

**Unstructured abstract (136/150)**

Gingival enlargements (GEs) can be caused by local, systemic diseases or drugs. Three molecules can be responsible of GEs: ciclosporin, phenytoin and calcium channel blockers (CCBs).

We report the case of a 56-year-old male treated by Amlodipine, a CCB, for hypertension for many years and who recently developed a severe GE affecting both mandibular and maxillary arches inducing dental malposition. The histological examination showed non-specific inflammation with a predominance of lymphocytes. Amlodipine was suspected and suspended in agreement with his physician. One month later, the enlargement significantly reduced but GE was so severe and dental malposition so marked that all the teeth but the canines were extracted. No recurrence was noted one year later.

This exceptional case should encourage every practitioner to be vigilant with patient treated with CCBs and their potential side effects and consequences.

**Keywords (4/6)**

Gingival Enlargement

Calcium Channel Blocker

Amlodipine

Iatrogeny

Text (1272 / 2000 words)

### **Introduction**

Gingival enlargements (GEs) refer to an excessive proliferation of gingival soft tissues. They impact functionally through speech and chewing, as well aesthetically.

Local or systemic diseases can be responsible of gingival enlargements and determining the aetiology is essential for appropriate management. Health practitioners must first exclude haematological malignancies and squamous cell carcinoma as any delay in the diagnosis could have a dramatic impact. Other aetiologies are represented by periodontal diseases, genetic diseases and iatrogeny. Three molecules are known to cause GEs: ciclosporin, phenytoin and calcium channel blockers (CCB). Bondon-Guitton et al. reported other treatments responsible for GEs such as immunosuppressants, anticonvulsants, antibiotics and contraceptive pill [1].

CCBs are frequently used to treat cardiovascular diseases such as hypertension, chronic, stable and vasospastic angina and cardiac arrhythmias. CCBs are divided in 2 groups based on their chemical structure: dihydropyridine (nifedipine, amlodipine) and non-dihydropyridine (diltiazem, verapamil, flunarizine) [2, 3]. CCBs inhibit calcium ion influx in cardiac and smooth cell muscles. They block voltage-dependant calcium channels, resulting in reduced contraction of arteries, lower arterial pressure and improved myocardial perfusion [3, 4].

Different prevalence rates have been reported for CCBs induced GEs. Nifedipine was reported to induce GEs in 43,6% of cases [5] and Amlodipine was 3,3% of cases [6].

In addition to GEs, CCBs can cause other adverse effects such as flushing, headaches, ankle oedemas, palpitations, tachycardia and constipation [7, 8].

Even though the link between GEs and CCBs is already established, it is relatively unknown by health practitioners, leading to delayed diagnoses. We present and discuss the case of a patient treated by CCB during 3 years, in whom GE subsequently developed. Our objectives were to determine the role played by CCB on GE and explain the physiopathology. We aimed to emphasize the need of thorough questioning by health practitioners to patients presenting GE.

### **Case report**

A 56-years-old man was referred to the Maxillofacial Surgery department for severe GE. His past medical history included hypertension, type 2 diabetes, renal failure, hepatitis C and a monoclonal gammopathy of undetermined significance (MGUS). He was treated daily by Amlodipine 10mg per day, Perindopril, Furosemide, Nebivolol and Insulin.

The patient had been treated by Amlodipine 10mg per day for three years.

The intraoral examination found an unusual presentation of GE as it was affecting both buccal and lingual/palatal sides, anterior and posterior teeth and predominant on anterior teeth (Figure 1). The superior canines were extremely mobile and were extracted to limit local inflammation. The panoramic radiograph revealed terminal periodontitis with dramatic bone loss (Figure 2). A biopsy was performed to eliminate malignant diseases considering the severity and the recent occurrence of the symptoms. Histological examination showed non-specific inflammatory overhaul with a predominance of lymphocytes (Figure 3).

As GEs are reported side effects of treatment by CCBs, Amlodipine was suspected to be responsible. In coordination with the patient's nephrologist, the treatment was suspended and not substituted.

One month after withdrawing Amlodipine, GE was significantly reduced (Figure 4). Remaining teeth were extremely mobile excepting lower canines. Mobile teeth were extracted and a mobile denture was made. One year later, no recurrence was found.

### **Discussion**

GEs may have various causes and it is crucial to determine their aetiology. After eliminating life-threatening diseases such as haematological diseases and squamous cell carcinoma, thorough questioning must focus on the patient's medical history and his treatment. There was a delayed diagnosis for our patient because the initial investigation was not rigorous enough, and several other diagnoses were discussed such as haematological disease. Various drugs including CCBs, ciclosporin and phenytoin were reported to be responsible of GEs [9, 10]. Among CCBs, Nifedipine is the most frequently implied [11, 12] but Amlodipine seems to be responsible of more severe GEs [4]. GEs usually appear after 2 to 15 months of treatment by CCB [13]. GEs can be localised or generalised to the entire dental arch, affecting preferentially anterior sectors and the buccal side, and spare edentulous crests. Cases are more or less severe, from mild papillary growth to enlargement of both marginal and papillary tissues. For our patient, the severity of the GE, affecting both buccal and palatal sides and both anterior and posterior sectors, associated with poor oral hygiene led to dental loss. Considering the unusual severity of the affection after only 3 years of treatment by amlodipine, we also cannot exclude the possibility of a moderate and hereditary pre-existent GE, unnoticed by the patient. Unfortunately, as the patient didn't have any dental follow-up before the GE appeared, this cannot be confirmed.

Histologically, drug induced-GE is related to chorion thickening. Biopsies have shown an important epithelial hyperplasia-acanthosis. Moderate inflammatory reaction is found in the

lamina propria. An accumulation of extracellular matrix proteins occurs in the chorion such as type-1 collagen, amorphous ground substance and non-collagenous proteins (e.g. glycosaminoglycans) [7]. Fibrosis is usually reported with fibroblastic proliferation and an increased number of capillaries. Histological aspects of our case were typical with a combination of inflammation and fibrosis, as shown on Figure 3.

The pathogenesis of CCBs-induced GE is not fully understood. In a review article, Trackman and Kantarci described GE as a consequence of the accumulation of extracellular matrix and an increased number of cells [10]. CCBs and other incriminated drugs promote inflammation through release of inflammatory mediators (e.g. TGF- $\beta$ ) by immune cells which activate fibroblasts [10] and enhances extracellular matrix biosynthesis. As poor oral hygiene also increases local inflammation, it leads to more severe GEs, well-illustrated with the presented case. Other studies reported that CCBs reduce the secretion of matrix metalloproteinases-1 and 3 and collagenases, leading to a decrease of the degradation of the extracellular matrix [7, 14]. Moreover, some studies described reduced apoptosis and increased cell proliferation, which induces the hyperplastic nature of gingival enlargement [7, 14, 15].

As only few patients treated by CCBs will develop GEs, a genetic predisposition with great variations in fibroblasts susceptibility to CCBs is suspected [7, 15]. Furthermore, CCBs are metabolized by hepatic cytochrome P450 enzymes. The polymorphism of this cytochrome results in interindividual variations of its efficacy and concentration of CCBs in serum and tissues. This could also explain the predisposition of individuals to develop side effects [7].

Treatment of drug-induced GEs first consists in stopping or substituting the suspected drug in coordination with the initial prescriber. When CCBs are responsible, use of another class of antihypertensive drug must be considered. This drug should not be reintroduced

because of a high frequency of recurrence [7]. This case confirmed that stopping the inducing drug reached to complete regression of clinical features. Nevertheless, it did not prevent dental loss. As expected, the GE regressed after we stopped the incriminated drug. However, the combination with poor oral hygiene led to a severe alveolar bone loss and ultimately teeth loss.

Oral hygiene is a crucial associated risk factor as poor oral hygiene leads to caries, strengthens periodontal inflammation and so alveolar bone resorption and ultimately teeth loss. Appropriate dental and periodontal care are then highly recommended, aiming to eliminate dental plaque and reduce inflammation. This patient presented such a severe alveolar bone loss that conservative management could not be considered. Gingivoplasty and gingivectomy can be performed to eliminate pockets and improve oral hygiene, but when alveolar bone-loss is too important like in this patient, numerous teeth loss lead to prosthetic rehabilitation. [7].

### **Conclusion**

CCBs are frequently prescribed and can be responsible of GEs. Health practitioners have to know this side effect for aetiological diagnosis. Early treatment is important as it can prevent periodontal damage and teeth loss by improvement of oral hygiene and reduction of gingival inflammation. The incriminated molecule should be stopped or substituted by the physician who initiated the treatment.

### **Funding source**

This research did not receive any specific grant from funding agencies in the public, commercial, or not-for-profit sectors.



**Conflict of interest**

This research did not receive any specific grant from funding agencies in the public, commercial or non-for-profit sectors.

**Acknowledgment**

The authors are indebted to Drs Madeleine Joubert, Karine Renaudin-Autain, Elisabeth Cassagnau, Nantes University Hospital, for analysing biopsy samples and for providing histological images.

ACCEPTED MANUSCRIPT

**References (15/15 max)**

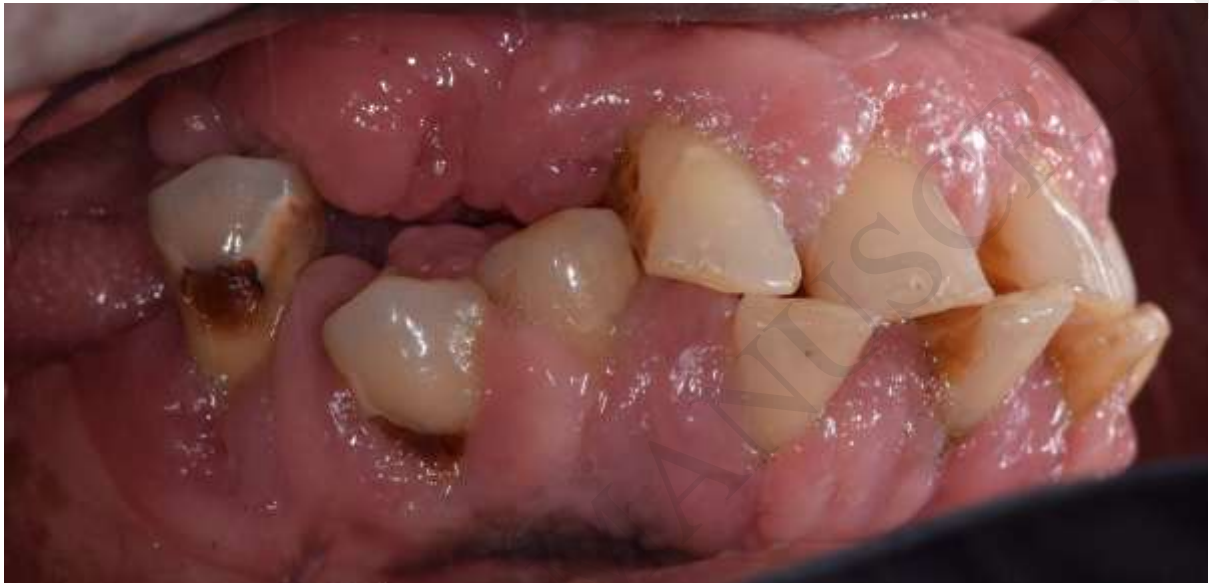1. Bondon-Guitton E, Bagheri H, Montastruc J-L, The French Network of Regional Pharmacovigilance Centers. Drug-induced gingival overgrowth: a study in the French Pharmacovigilance Database. *Journal of Clinical Periodontology*. 2012 Jun;39(6):513–8.
2. Toyo-Oka T, Nayler WG. Third Generation Calcium Entry Blockers. *Blood Pressure*. 1996 Jan;5(4):206–8.
3. Godfraind T. Calcium Channel Blockers in Cardiovascular Pharmacotherapy. *Journal of Cardiovascular Pharmacology and Therapeutics*. 2014 Nov;19(6):501–15.
4. Umezudike K, Olawuyi A, Umezudike T, Olusegun-Joseph A, Bello B. Effect of calcium channel blockers on gingival tissues in hypertensive patients in Lagos, Nigeria: A pilot study. *Contemporary Clinical Dentistry*. 2017;8(4):565.
5. Nery EB, Edson RG, Lee KK, Pruthi VK, Watson J. Prevalence of Nifedipine-Induced Gingival Hyperplasia. *Journal of Periodontology*. 1995 Jul;66(7):572–8.
6. Jorgensen MG. Prevalence of Amlodipine-Related Gingival Hyperplasia. *Journal of Periodontology*. 1997 Jul;68(7):676–8.
7. Livada R, Shiloah J. Calcium channel blocker-induced gingival enlargement. *Journal of Human Hypertension*. 2014 Jan;28(1):10–4.
8. Dougall HT, McLay J. A Comparative Review of the Adverse Effects of Calcium Antagonists: Drug Safety. 1996 Aug;15(2):91–106.
9. Sibaud V, Vigarios E, Tavitian S, Cougoul P, de Bataille C, Campana F, et al. Accroissements gingivaux : approche pragmatique. *Annales de Dermatologie et de Vénérologie*. 2016 Jun;143(6–7):467–81.
10. Trackman PC, Kantarci A. Molecular and Clinical Aspects of Drug-induced Gingival Overgrowth. *Journal of Dental Research*. 2015 Apr;94(4):540–6.
11. Vidal F, de Souza RC, Ferreira DC, Fischer RG, Gonçalves LS. Influence of 3 calcium channel blockers on gingival overgrowth in a population of severe refractory hypertensive patients. *Journal of Periodontal Research*. 2018 Oct;53(5):721–6.
12. Ellis JS, Seymour RA, Steele JG, Robertson P, Butler TJ, Thomason JM. Prevalence of Gingival Overgrowth Induced by Calcium Channel Blockers: A Community-Based Study. *Journal of Periodontology*. 1999 Jan;70(1):63–7.
13. Hatahira H, Abe J, Hane Y, Matsui T, Sasaoka S, Motooka Y, et al. Drug-induced gingival hyperplasia: a retrospective study using spontaneous reporting system databases. *Journal of Pharmaceutical Health Care and Sciences [Internet]*. 2017 Dec [cited 2019 Jan 24];3(1). Available from: <http://jphcs.biomedcentral.com/articles/10.1186/s40780-017-0088-5>

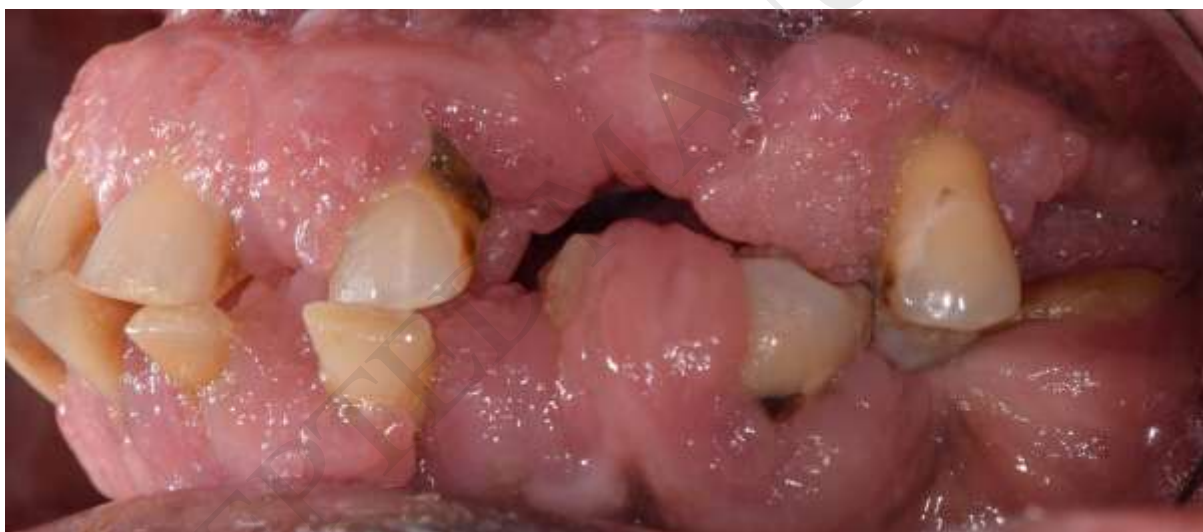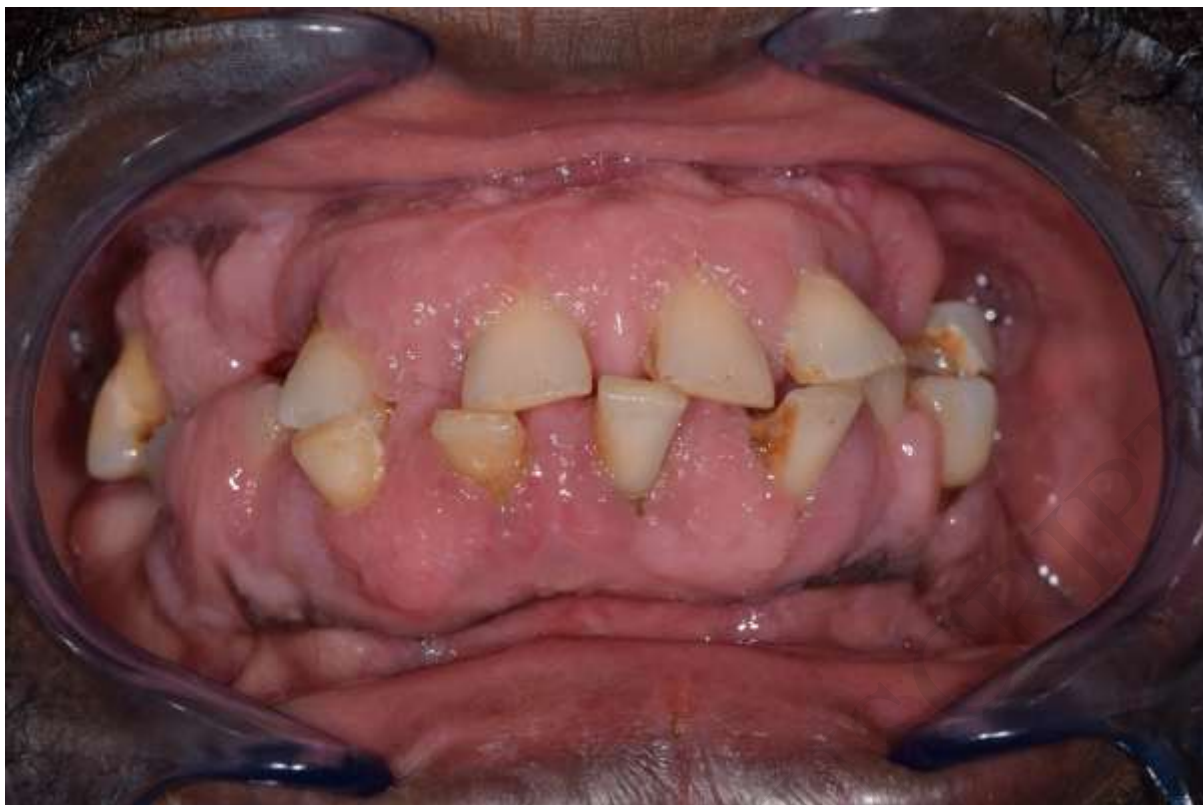14. Dongari-Bagtzoglou A. Informational Paper: Drug-Associated Gingival Enlargement. *Journal of Periodontology*. 2004 Oct;75(10):1424–31.
15. Joshi S, Bansal S. A Rare Case Report of Amlodipine-Induced Gingival Enlargement and Review of Its Pathogenesis. *Case Reports in Dentistry*. 2013;2013:1–3.

ACCEPTED MANUSCRIPT

**Figure captions (4/6 max)**

Figure 1: Gingival enlargement affecting both buccal and lingual/palatal sides, predominantly on anterior teeth. a: right lateral view, b: frontal view, c: left lateral view, d: maxillary arch, e: mandibular arch.





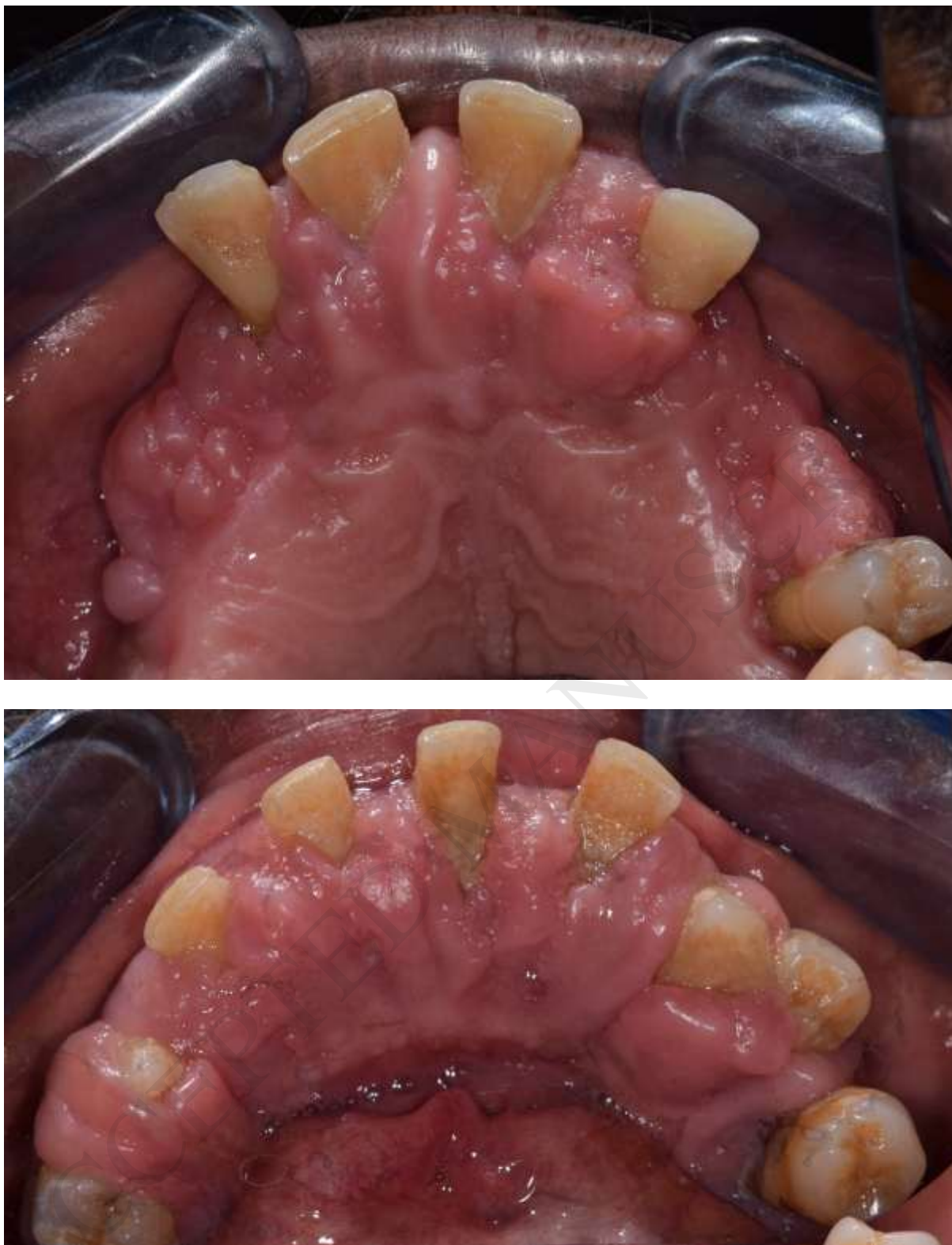

Figure 2: Panoramic radiograph showing terminal periodontitis with important bone loss.



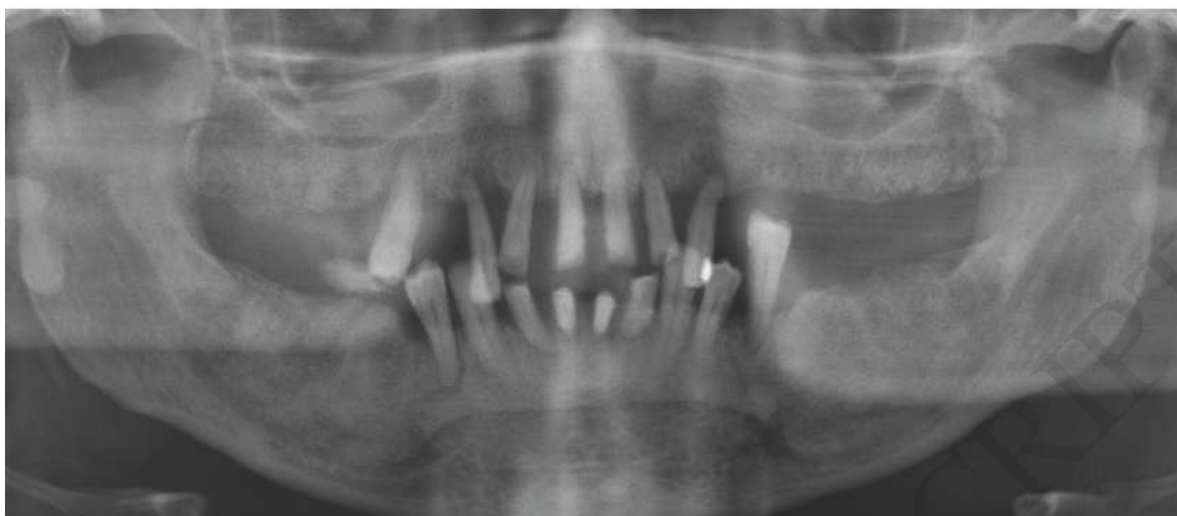

Figure 3: Gingival biopsy examination shows epithelial hyperplasia with hyperkeratosis without dysplasia. The chorion shows fibrosis and lymphocytic infiltration predominant around the blood vessels. (haematoxylin eosin stain, original magnification x100)

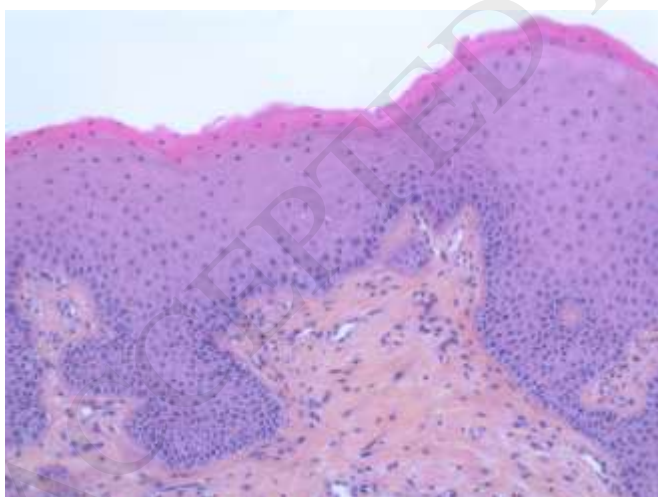
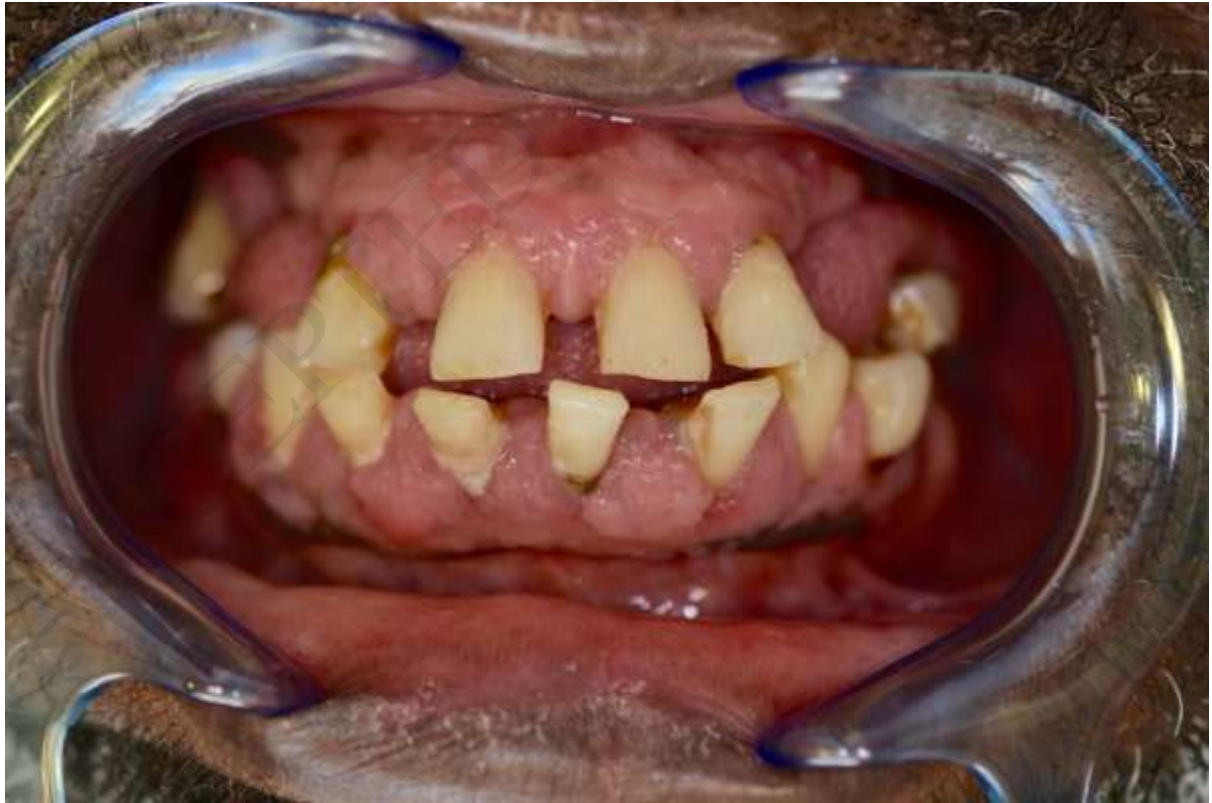
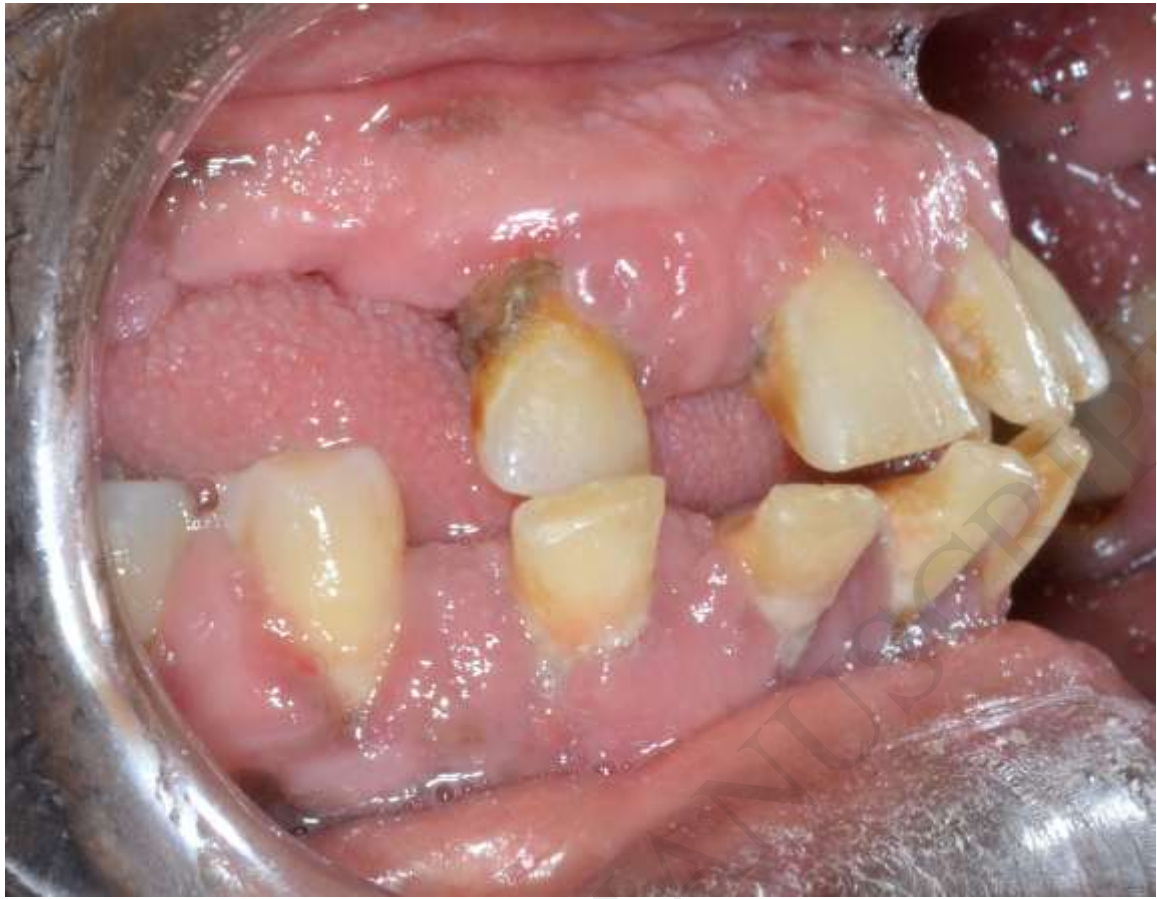
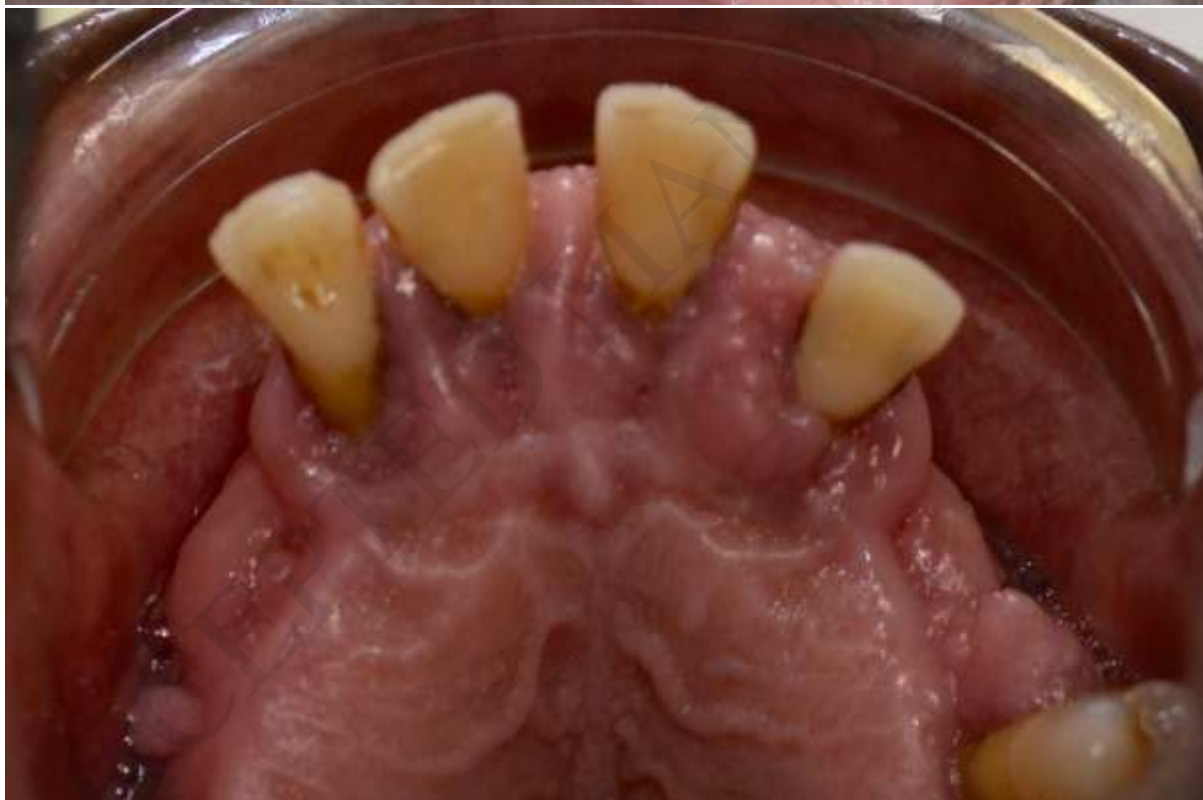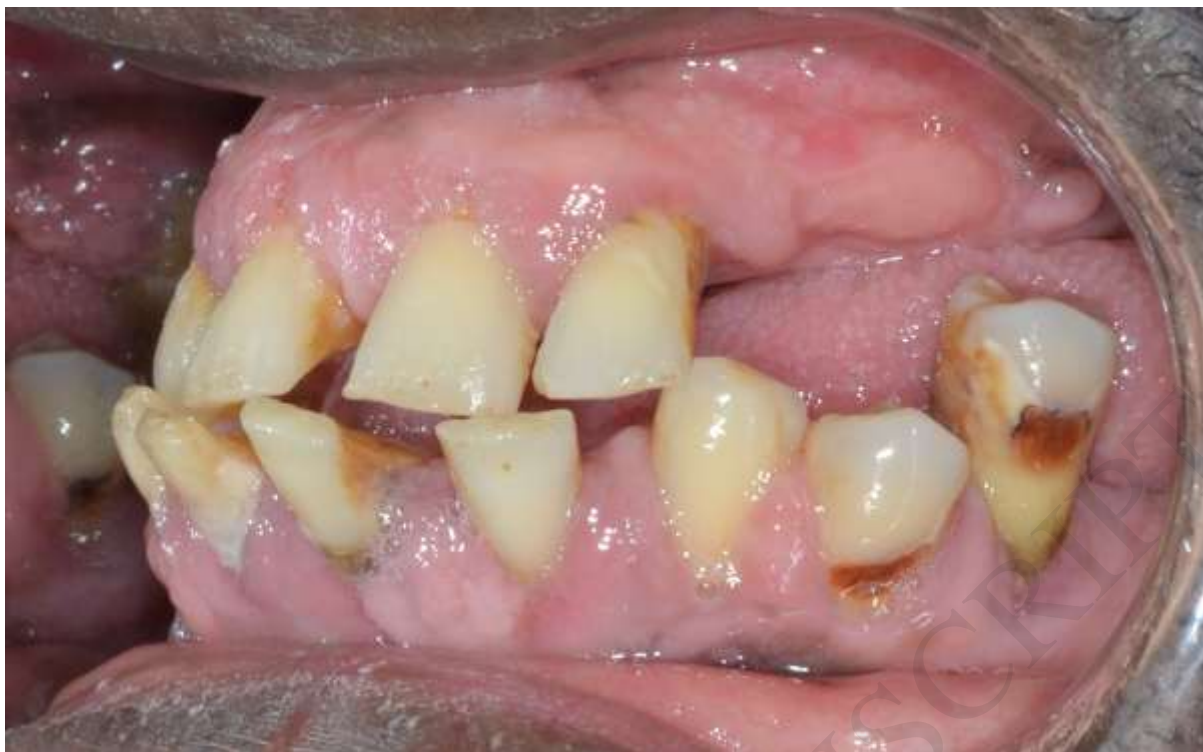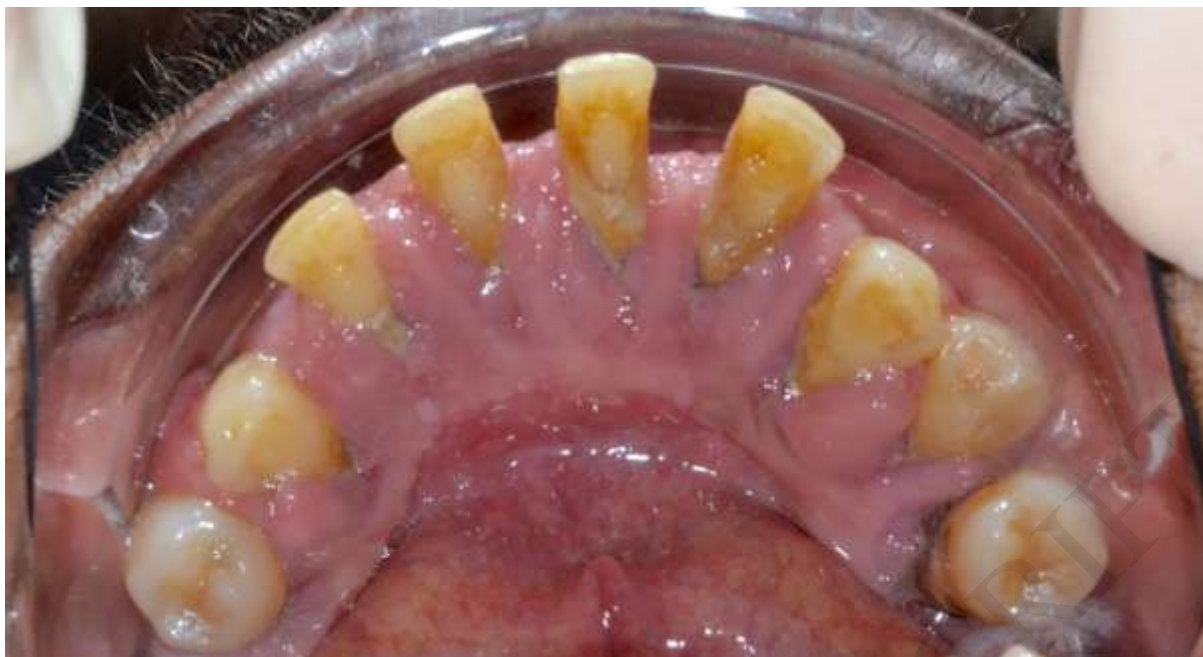Figure 4: One-month follow-up. Gingival enlargement reduced after stopping the treatment by amlodipine. a: right lateral view, b: frontal view, c: left lateral view, d: maxillary arch, e: mandibular arch.









ACCEPTED MANUSCRIPT