



ELSEVIER

Available online at
ScienceDirect
www.sciencedirect.com

Elsevier Masson France
EM|consulte
www.em-consulte.com/en



REVIEW

Position paper for the evaluation and management of oral status in patients with valvular disease: Groupe de Travail Valvulopathies de la Société Française de Cardiologie, Société Française de Chirurgie Orale, Société Française de Parodontologie et d'Implantologie Orale, Société Française d'Endodontie et Société de Pathologie Infectieuse de Langue Française



Point de vue d'experts sur l'évaluation et la prise en charge buccodentaire des patients atteints de cardiopathies valvulaires

Sarah Millot^{a,b}, Philippe Lesclous^c,
Marie-Laure Colombier^d, Loredana Radoi^e,
Clément Messeca^f, Mathieu Ballanger^g,
Jean-Luc Charrier^h, Philippe Trambaⁱ,
Stéphane Simon^j, Alain Berrebi^k, Fabien Doguet^l,
Emmanuel Lansac^m, Christophe Tribouilloyⁿ,
Gilbert Habib^o, Xavier Duval^p, Bernard Iung^{q,*}

^a Department of oral surgery, Montpellier university hospital, 34295 Montpellier, France

^b Inserm 1149, 75018 Paris, France

^c Department of oral surgery, Nantes hospital, university of Nantes, Inserm U791, LIOAD, 44093 Nantes, France

Abbreviations: AHA, American Heart Association; CHD, Congenital heart disease; CBCT, Cone beam computed tomography; ESC, European society of cardiology; IE, Infective endocarditis.

* Corresponding author. Cardiology department, Bichat hospital, 46, rue Henri-Huchard, 75018 Paris, France.

E-mail address: bernard.iung@aphp.fr (B. Iung).

<http://dx.doi.org/10.1016/j.acvd.2017.01.012>

1875-2136/© 2017 Elsevier Masson SAS. All rights reserved.

^d Department of periodontology, Louis-Mourier hospital, AP–HP, university of Paris Descartes, 92700 Colombes, France

^e Department of oral surgery, Louis-Mourier hospital, AP–HP, university of Paris Descartes, Inserm U1018, 92700 Colombes, France

^f Odontology department, Bichat hospital, AP–HP, 75018 Paris, France

^g Department of oral surgery, Pitié-Salpêtrière hospital, AP–HP, university of Paris Descartes, 75013 Paris, France

^h Department of oral surgery, Bretonneau hospital, AP–HP, university of Paris Descartes, 75018 Paris, France

ⁱ Department of implantology and prosthetics, Pitié Salpêtrière hospital, AP–HP, university of Paris Descartes, 75013 Paris, France

^j Endodontics department, Pitié-Salpêtrière hospital, AP–HP, Paris-Diderot university, 75013 Paris, France

^k Department of cardiology, Georges Pompidou european hospital, AP–HP, institut mutualiste Montsouris, 75014 Paris, France

^l Department of thoracic and cardiovascular surgery, Rouen university hospital, Inserm U1096, 76000 Rouen, France

^m Department of cardiac surgery, institut mutualiste Montsouris, 75014 Paris, France

ⁿ Department of cardiology, university hospital of Amiens, Inserm U1088, Jules-Verne university of Picardie, 80480 Amiens, France

^o Department of cardiology, La Timone hospital, Aix-Marseille university, 13385 Marseille, France

^p Centre of clinical investigations, Inserm 1425, Bichat hospital, AP–HP, Paris-Diderot university, Inserm U1137, AEPEI, 75018 Paris, France

^q Department of cardiology, Bichat hospital, AP–HP, DHU FIRE, Paris-Diderot university, 46, rue Henri-Huchard, 75018 Paris, France

Received 25 November 2016; received in revised form 20 January 2017; accepted 23 January 2017

Available online 16 June 2017

KEYWORDS

Dental implant;
Infective
endocarditis;
Oral infectious foci;
Periodontitis;
Valvular heart disease

Summary Oral health is of particular importance in patients with heart valve diseases because of the risk of infective endocarditis. Recommendations for antibiotic prophylaxis before dental procedures have been restricted, but the modalities of oral evaluation and dental care are not detailed in guidelines. Therefore, a multidisciplinary working group reviewed the literature to propose detailed approaches for the evaluation and management of buccodental status in patients with valvular disease. Simple questions asked by a non-dental specialist may draw attention to buccodental diseases. Besides clinical examination, recent imaging techniques are highly sensitive for the detection of inflammatory bone destruction directly related to oral or dental infection foci. The management of buccodental disease before cardiac valvular surgery should be adapted to the timing of the intervention. Simple therapeutic principles can be applied even before urgent intervention. Restorative dentistry and endodontic and periodontal therapy can be performed before elective valvular intervention and during the follow-up of patients at high risk of endocarditis. The detection and treatment of buccodental foci of infection should follow specific rules in patients who present with acute endocarditis. Implant placement is no longer contraindicated in patients at intermediate risk of endocarditis, and can also be performed in selected high-risk patients. The decision for implant placement should follow an analysis of general and local factors increasing the risk of implant failure. The surgical and prosthetic procedures should be performed in optimal safety conditions. It is therefore now possible to safely decrease the number of contraindicated dental procedures in patients at risk of endocarditis.

© 2017 Elsevier Masson SAS. All rights reserved.

MOTS CLÉS

Implant dentaire ;
Endocardite

Résumé L'hygiène buccodentaire revêt une importance particulière chez les patients présentant une cardiopathie valvulaire en raison du risque d'endocardite infectieuse. Les indications d'antibioprophylaxie ont été restreintes mais les modalités de l'évaluation et des soins

infectieuse ;
Foyers infectieux
oraux ;
Parodontopathie ;
Valvulopathie

buccodentaires ne sont pas détaillées dans les recommandations. Ceci a conduit à un groupe de travail multidisciplinaire à analyser la littérature afin de proposer des approches détaillées pour l'évaluation et la prise en charge buccodentaire chez les patients ayant une cardiopathie valvulaire. Des questions simples posées par un non-spécialiste peuvent attirer l'attention sur de possibles lésions buccodentaires. En plus de l'examen clinique, des techniques d'imagerie récentes sont très sensibles pour la détection de destructions osseuses inflammatoires d'origine infectieuse orales ou dentaires. Avant une intervention valvulaire, la prise en charge de lésions buccodentaires doit être adaptée à la chronologie de l'intervention. Des traitements simples peuvent être appliqués même avant une intervention urgente. Des soins dentaires conservateurs et endodontiques peuvent être effectués avant une intervention valvulaire électorale et durant le suivi de patients à haut risque d'endocardite. La détection et le traitement des foyers infectieux buccodentaires doit suivre des règles spécifiques chez les patients présentant une endocardite aiguë. La mise en place d'implants n'est plus contre-indiquée chez les patients à risque intermédiaire d'endocardite et peut être effectuée aussi chez certains patients à haut risque. La décision de mise en place d'un implant dentaire doit suivre une analyse des facteurs généraux et locaux augmentant le risque d'échec implantaire. Les procédures chirurgicales et prothétiques doivent être réalisées dans des conditions optimales de sécurité. Il est donc désormais possible de réduire le nombre de procédures dentaires contre-indiquées chez les patients à risque d'endocardite.

© 2017 Elsevier Masson SAS. Tous droits réservés.

Background

Oral health should be part of hygiene measures in the general population, but it is of particular importance in patients with valvular heart disease because of the risk of infective endocarditis (IE), which can be caused by bacteraemia of buccodental origin. The risk of IE has led, over a long period of time, to wide indications for antibiotic prophylaxis before invasive procedures and to the aggressive management of dental diseases, particularly the contraindication of most conservative procedures and implant placement [1]. The last decade has been marked by changes in the pathophysiological concepts of IE, and by innovations in imaging and techniques for dental care. Regarding the prevention of IE, recent guidelines have consistently reduced indications for antibiotic prophylaxis, and highlight the need for buccodental hygiene [2–7]; however, they do not address in detail the specific issue of the modalities of buccodental evaluation and management in patients with heart valve diseases.

The working group on valvular disease of the French Society of Cardiology, the French Society of Oral Surgery, the French Society of Periodontology and Implantology, the French Society of Endodontics and the Francophone Society of Infectious Disease took the initiative of setting up a multidisciplinary working group to review the current literature. This document proposes detailed approaches for the evaluation and management of buccodental status in patients with valvular disease according to the clinical context, and updated principles for therapeutic management, with a particular emphasis on oral implantology.

Literature search

For the different subject headings, we conducted a series of literature searches in Medline via the PubMed database of the United States National Library of Medicine, for

articles published in English from January 2000 until October 2016, using the following key words: dental implant; oral hygiene; oral bacteraemia; infective endocarditis; peri-implantitis; endodontic therapy; periodontitis; smoking; diabetes; rheumatoid arthritis; valvular disease; and immunosuppressive therapies. The search strategy included clinical and experimental studies, systematic reviews and meta-analyses.

Current presentation of IE and recommendations for prophylaxis

The annual incidence of IE is estimated at 30 per million inhabitants in France, which represents 1500 to 2000 cases per year [8]. Treatment requires prolonged intravenous antibiotic therapy, and half of patients undergo valvular surgery during the acute phase of IE. Mortality remains high: approximately 20% for in-hospital mortality, and 40% at 4 years. The distribution of the responsible microorganisms has changed over time, with a decrease in the frequency of oral *streptococci*, which now account for 19% of cases in France, while *staphylococci* have become the most frequent cause of IE, in 35% of cases [8,9].

Prevention of IE initially focused on antibiotic prophylaxis to reduce transient high-grade bacteraemia occurring during invasive procedures, particularly dental care. It is now recognized that low-grade but repeated bacteraemia occurs during daily-life activities (tooth brushing, chewing, etc.) and may cause IE on diseased valves [10,11]. These daily low-grade bacteraemias are not amenable to antibiotic prophylaxis, but depend on oral hygiene, and represent a rationale for the detection and treatment of all infectious oral foci in patients at risk of IE.

Indications for antibiotic prophylaxis before oral care are now restricted to patients at high risk of IE (Table 1)

Table 1 Cardiac conditions at highest risk of infective endocarditis for which prophylaxis should be considered when a high-risk procedure is performed; from the 2015 European society of cardiology guidelines for the management of infective endocarditis [5].

Recommendations	Class of recommendation	Level of evidence
<p><i>Antibiotic prophylaxis should be considered for patients at highest risk for IE</i></p> <p>Patients with any prosthetic valve, including a transcatheter valve, or those in whom any prosthetic material was used for cardiac valve repair</p> <p>Patients with a previous episode of IE</p> <p>Patients with CHD</p> <p>Any type of cyanotic CHD</p> <p>Any type of CHD repaired with a prosthetic material, whether placed surgically or by percutaneous techniques, up to 6 months after the procedure or lifelong if residual shunt or valvular regurgitation remains</p>	Ila	C
<p><i>Antibiotic prophylaxis is not recommended in other forms of valvular heart disease or CHD</i></p>	III	C

CHD: congenital heart disease; IE: infective endocarditis.

[5]. The recommended regimen of antibiotic prophylaxis is the administration of 2 g of amoxicillin, 30 to 60 minutes before the dental procedure, or 600 mg of clindamycin in case of allergy to penicillin. Patients at intermediate risk of IE are those with native valve disease, congenital heart disease (CHD) with left-to-right shunts except atrial septal defects and hypertrophic cardiomyopathy. Antibiotic prophylaxis is not indicated in intermediate-risk patients. In all patients, general and dental hygiene measures are mandatory.

General principles of oral evaluation of patients with heart valve disease

General recommendations have been provided for the diagnosis and management of oral foci of infections [12]. The search for oral infectious foci (dental, periodontal, mucosal) and their management in patients at risk of IE correspond to different situations, and should therefore be adapted.

In addition to general principles, the working group proposes to address the clinical examination and work conducted during these consultations in three distinctive

situations: specific oral consultation before valve replacement/repair; specific oral consultation during the acute phase of IE; and specific oral consultation for high-risk patients.

Clinical evaluation by the non-dental specialist

General practitioners, cardiologists and cardiac surgeons are generally the first practitioners involved in the initial evaluation or follow-up of patients either with native heart valve diseases or after valvular surgery. It is therefore of importance that these practitioners are aware of certain simple questions to be asked at each visit (Table 2). A positive answer to any of these questions reveals a concern, and should lead to a prompt specific consultation with a dental surgeon.

Clinical evaluation by the odontologist

The dentist's consultation should include a complete clinical examination, as detailed in Table 3.

Table 2 Standard questions to be asked by the non-specialist to patients with valvular heart disease.

Do your teeth hurt?
Do your gums hurt or bleed during brushing or spontaneously?
Do you think that your teeth move or that they have moved?
Do you have the impression that you have a bad taste or a bad breath in your mouth?
Do you feel uncomfortable in your mouth?
Have you lost some teeth recently?
Do you feel a swelling in your mouth?
Have you noticed a colour change in one of your teeth?

At least one positive answer should lead to a consultation with a dentist.

Table 3 Clinical examination by the odontologist.

Signs, symptoms	Pain, swelling, suppuration, halitosis, bleeding
Dental examination	Evaluation of caries risk, teeth mobility, percussion and vitality
Periodontal examination	Plaque accumulation, calculus deposits, inflammation, pocket depth
Mucosal examination	Labial, jugal, lingual

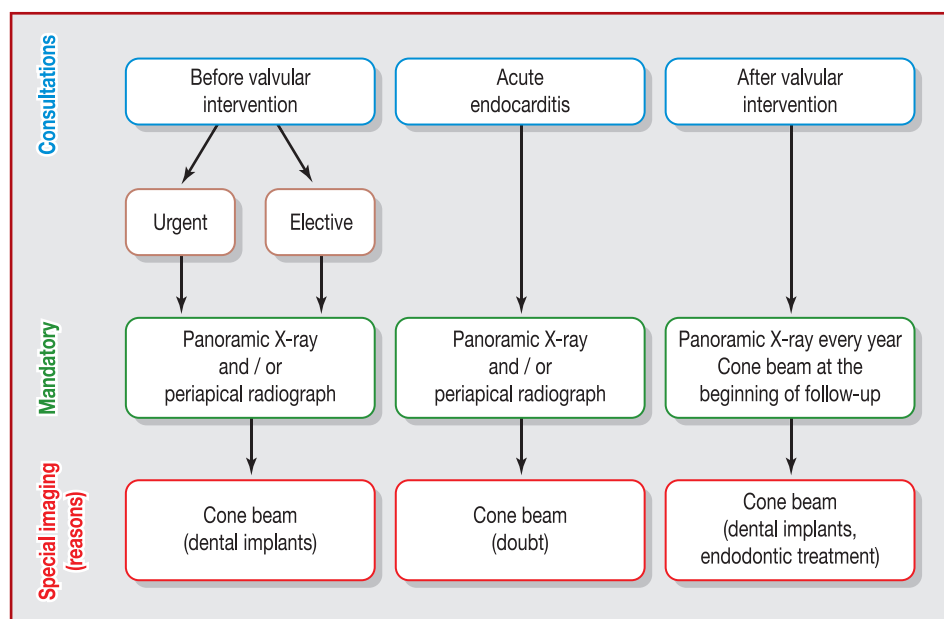


Figure 1. Indications for imaging according to clinical context.

Imaging techniques

Additional imaging investigations are mandatory for a careful search for oral infectious foci. A panoramic X-ray should be performed systematically [12], but other imaging techniques should be considered according to the clinical context, particularly in doubtful cases (Fig. 1).

Other investigations, such as computed dental tomography and large filed cone beam computed tomography (CBCT) should be indicated according to the patient's risk of IE, the clinical context, the findings of clinical examination by the odontologist and the therapeutic decision.

Conventional radiography (intraoral techniques, panoramic X-ray) provides only a two-dimensional view of three-dimensional complex structures, which can lead to underestimation of bone loss, apical radiolucencies, apical periodontitis, root number and morphology. Indeed, the persistence of the buccal cortical bone induces a false-positive X-ray result, as it hides medullar bone resorption. CBCT is a widely used diagnostic method in dentomaxillofacial radiology, showing excellent accuracy with relatively low cost and low radiation dose. Recent studies underline an important difference in sensitivity in the detection of periapical radiolucencies, depending on the imaging techniques used (28%, 55% and 100% for panoramic X-ray, periapical X-ray and CBCT, respectively). Three-dimensional imaging reveals a higher prevalence of periapical radiolucencies and better exploration in the maxillomandibular complex (nerve location, bone thickness, superposition of maxillary sinus) versus conventional radiography [13–15].

The working group proposes that CBCT should be used in certain demanding situations where high sensitivity is needed for the detection of oral infectious foci, notably in the presence of root canal-treated teeth or if there is any other doubt about the endodontic status of restored teeth or periapical lesions. The performance of CBCT is also

recommended at the beginning of follow-up after valvular intervention.

Oral management of patients with heart valve disease: specific situations

Before valve intervention

The majority of patients who will undergo valvular intervention have native valve disease, and are therefore at intermediate risk of IE. However, it should be anticipated that these patients will become at high risk of IE after valve intervention, whether it is surgical valve replacement or repair, or transcatheter valve implantation. Therefore, a thorough search for and treatment of oral infectious foci are needed before valvular intervention, but their modalities should be adapted to the timing of the valvular intervention. Valvular intervention concerns prosthetic valve replacement, valve repair or transcatheter valve implantation, as patients will be at high risk of IE after any of these procedures [5].

Urgent surgery (within 1 week)

When there is an indication for urgent valvular intervention, there is only a short time available for odontological evaluation and, even more so, for treatment. The aim is to detect the most active infectious sites, which are often associated with pain or swelling, to limit the bacterial load and the risk of high-grade bacteraemia. Oral evaluation is limited to a clinical examination and, if possible, is completed by panoramic X-ray.

Therapeutic management

Therapeutic management involves: elimination of oral acute infectious foci (facial cellulitis, periodontal abscess, acute pericoronitis) (Fig. 2); extraction of compromised teeth with symptomatic apical periodontitis or pathological mobility

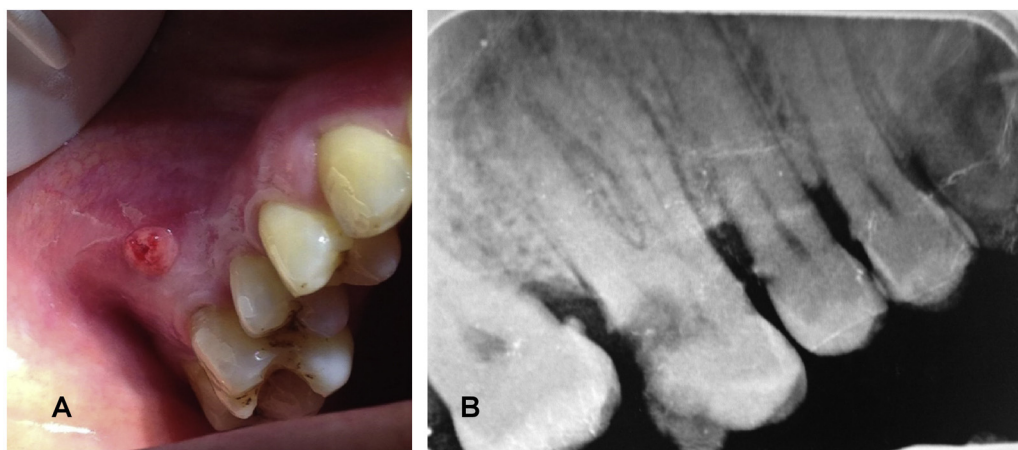


Figure 2. Clinical and radiographic views of oral acute infectious foci. A. Intraoral fistula of endodontic origin (necrosis of the first right molar). B. Intraoral radiograph showing a large decay affecting the dental pulp of this tooth and periapical radiolucency.

(no healing time between extractions and cardiac surgery is required in these situations); preoperative oral decontamination with chlorhexidine 0.12% or 0.2%, 24 hours before cardiac surgery (mouth rinse for 1 minute after each meal); scaling, if it can be performed at least 48 hours before surgery; and a written report to the cardiologist regarding orodental therapeutic decisions before surgery and detailed instructions for modalities of additional dental care and follow-up after valvular surgery.

The usefulness of preoperative oral decontamination with chlorhexidine remains a matter of debate. American Heart Association (AHA) guidelines initially suggested the need to combine antibiotic prophylaxis with chlorhexidine disinfection for high-risk IE patients [16]; this was also advised by the British Society for Antimicrobial Chemotherapy in 1992 [17]. In 1997, the AHA recognized the need to use antiseptic mouthwash before dental manipulation [18]. In 2006 the 0.2% chlorhexidine mouthwash protocol (10 mL for 1 minute) was recommended before any dental manipulation to diminish postoperative bacteraemia [3].

Conversely, in 2007 and 2008, the AHA and National Institute for Health and Care Excellence no longer recommended the use of antiseptics before dental procedures, following study results that underlined that bacteraemia was not significantly reduced by this disinfection [6,7].

Recently, studies involving a larger number of patients showed that the use of 0.2% chlorhexidine mouthwash before dental procedures decreased postoperative bacteraemia [19–21]. In addition, perioperative oral chlorhexidine significantly decreases the incidence of nosocomial infection and postoperative pneumonia in patients undergoing elective cardiac surgery [22–24].

Despite discrepancies, current evidence has led the working group to suggest the use of 0.12% or 0.2% chlorhexidine mouthwash 1 day systematically before valvular intervention.

Before elective surgery

Patients undergoing elective surgery are most often at intermediate risk of IE, and invasive (conservative) dental procedures are not contraindicated. In these situations

where the indication for surgery is not urgent, odontological evaluation should be performed weeks before the intervention to allow enough time for optimal dental care, if needed.

The odontologist has a major preventative role, and should consider conservative dental care, always keeping in mind that after valve replacement or repair, the patient will be at high risk of IE with inherent contraindicated procedures.

The goal throughout these consultations is also to emphasize the importance of odontological follow-up after valve surgery.

Therapeutic management

Non-conservative procedures are mandatory in the following cases: elimination of oral acute infectious foci (facial cellulitis, periodontal abscess, acute pericoronitis); and extraction of compromised teeth with symptomatic apical periodontitis or pathological mobility. Alternative therapeutic options can be considered in selected cases, detailed below.

Periodontal management: exploration of periodontal status

Periodontal management involves non-surgical therapy (oral health education, scaling, root planning, maintenance). Recent investigations have shown that the maintenance of oral hygiene by regular scaling may reduce the risk of infectious diseases [25,26]. The working group proposes periodontal treatment before surgery.

Restorative dentistry and endodontic therapy: dental caries management

To limit the risk of dental caries and its sequelae, the group proposes the daily topical application of fluoride gel (1%) by means of custom-fabricated carriers [27]. The discovery of apical endodontic radiolucencies without symptoms (pain or swelling) or the presence of deep caries on a molar should lead to the consideration of endodontic therapy as a first-line treatment rather than systematic tooth extraction (see section entitled “Oral follow-up of patients at high risk of IE” for details).

Oral implantology

Implant placement is no longer contraindicated in patients at intermediate risk of IE [28]. However, when valve intervention is planned, we propose that the same precautions should be taken as in high-risk patients (see section entitled "Oral implantology in patients at high risk of IE").

Patient information

Patient information on meticulous oral hygiene, including recall programmes after valve intervention, should be provided.

During acute IE

This is a less frequent situation, which is part of the search for a portal of entry during the management of acute IE; it should be performed regardless of the microorganism involved, as patients with IE are at high risk of recurrent IE, which may be due to other microorganisms.

The need for high sensitivity in the detection of dental infectious foci in the context of acute IE leads the working group to recommend the systematic performance of CBCT (Fig. 3).

Of course, valvular surgery should not be postponed if there is an emergent or urgent indication and, in these cases, an additional odontological workup will be performed after surgery. Because IE requires prolonged antibiotic therapy and close initial follow-up, it is important to take the opportunity of the duration of hospital stay to perform a complete evaluation of oral status and to initiate dental care, if needed.

Therapeutic management

Therapeutic management involves: elimination of oral acute infectious foci (facial cellulitis, periodontal abscess, acute pericoronitis); extraction of compromised teeth with symptomatic apical periodontitis or pathological mobility; and preoperative oral decontamination with chlorhexidine 0.12%, 24 hours before cardiac surgery (see section entitled "Urgent surgery [within 1 week]).

No conservative dental procedures are considered in patients with acute IE, as patients with previous IE are at particularly high risk of IE recurrence [29,30].

Oral follow-up of patients at high risk of IE

Heart diseases at high risk of IE are detailed in Table 1. These situations are characterized, not only by a higher incidence of IE, but also by higher morbidity and mortality as a result of IE compared with patients at intermediate risk of IE.

A number of dental procedures were initially contraindicated in patients at high risk of IE [1]. There is a consensus for careful maintenance of oral health, and odontological follow-up is recommended every 4–6 months [12]. This is, however, applied infrequently in practice [31]. Anticoagulant therapy is also given frequently, and is systematic in patients with mechanical prostheses, but should not be a limitation, as most dental procedures can be performed under oral anticoagulant therapy [32,33].

Among high-risk patients, supplementary caution is needed for patients with a history of IE.

Therapeutic management

Therapeutic management involves: elimination of oral acute infectious foci (facial cellulitis, periodontal abscess, acute pericoronitis); and extraction of compromised teeth with symptomatic apical periodontitis or pathological mobility. Other possible therapeutic options are detailed below.

Periodontitis management

Periodontitis management involves initial non-surgical therapy (oral health education, scaling, root planning, maintenance).

Restorative dentistry and endodontic therapy

Restorative dentistry and endodontic therapy were initially contraindicated in these patients [1], but this was not based on evidence, and other guidelines did not provide the same restrictions [2–5,7]. Contraindicated dental procedures initially include, in particular, endodontic treatment of necrotic teeth. Only single-rooted and treatable vital teeth can be treated in one session under a dam [1]. However, deep caries management with pulpectomy and endodontic therapy of necrotic teeth is likely to be performed, with a low risk of infectious complications, even in high-risk patients. There is growing evidence from the literature that bacteraemia caused by endodontic treatment is low, and less than many other oral dental procedures requiring antibiotic prophylaxis [34]. In routine consultation, the discovery of apical radiolucencies or the presence of deep caries on a molar was initially considered to require tooth extraction [1]. Recent studies suggest that CBCT is a valuable adjunct in diagnosis, treatment planning and post-treatment assessment after endodontic procedures [35,36]. The working group proposes allowing endodontic therapy for teeth diagnosed with pulpitis or pulp necrosis, but also for teeth presenting apical periodontitis related to endodontic infection.

In parallel to the clinical diagnosis, the difficulty of treatment and the expertise of the clinician must also be considered. When the treatment can be completed in one session with a low risk of infected debris propulsion over the apical foramen of the tooth, endodontic treatment and some retreatments should be considered. CBCT imaging is a useful tool to estimate the difficulty of the treatment to be carried out. These patients should be referred to a specialist practitioner (specialist in endodontics or in oral and dental medicine) who is trained to perform these types of treatments in ideal conditions to avoid any infectious disease. Of course, these treatments must be performed under antibiotic prophylaxis.

Dental implants

The use of dental implants is no longer contraindicated in patients at high risk of IE, but should be discussed individually after cardiac recovery, stabilization of anticoagulant treatments and regular dental follow-up (see section entitled "Oral implantology in patients at high risk of IE").

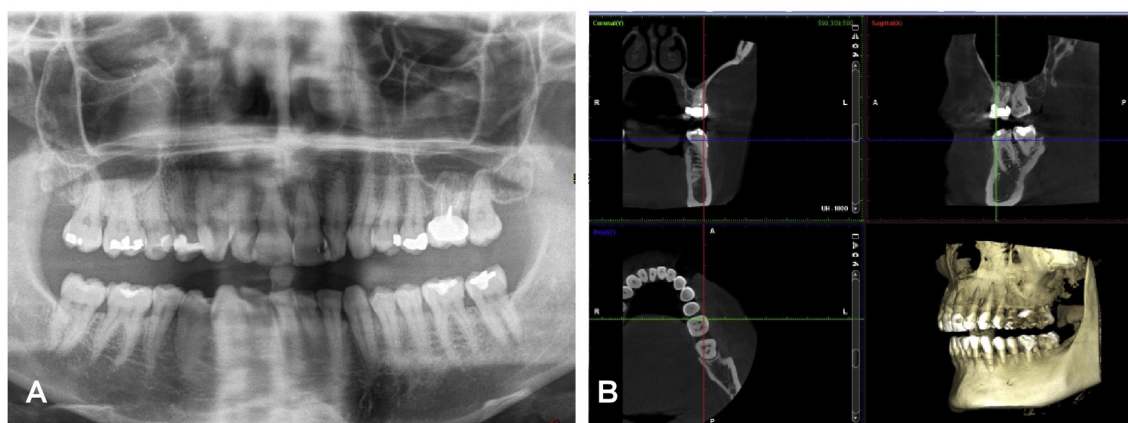


Figure 3. Imaging techniques during acute infective endocarditis. A. Initial panoramic X-ray showing doubtful radiolucency involving the apex of the maxillary left molar. B. Observation of the lesion with three-dimensional cone beam computed tomography imaging, confirming periapical lesions of the maxillary left molar and showing additional bone destruction.

Oral implantology in patients at high risk of IE

The objective is to propose a “framework of implant practice” in patients at high risk of IE, taking into account the risk of implant failure or infectious complication.

Evolution of recommendations

In the 2002 French consensus, the use of dental implants was contraindicated in any patient at intermediate or high risk of IE [1], because of concerns regarding the risk of infectious complications and the lack of data. In 2011, a document from the *Agence nationale de sécurité du médicament et des produits de santé* (ANSM) allowed the use of dental implants in patients at intermediate risk of IE, but maintained the contraindication in patients at high risk [28]. The use of dental implants was not addressed in the 2009 European Society of Cardiology (ESC) guidelines on IE or in guidelines from the USA [2,4,7,37]. Recently, the 2015 ESC guidelines stated that “The opinion of the Task Force is that there is no evidence to contraindicate implants in all patients at risk. The indication should be discussed on a case-by-case basis. The patient should be informed of the uncertainties and the need for close follow-up” [5].

However, very few clinical data are available. An observational study did not report infectious complications during a 2- to 18-year follow-up of patients at high risk of IE who received dental implants [38]. The relevance of these findings is limited by small sample size (57 implants in 13 patients with 16 implant placement procedures).

Dental implants are now widely used to replace missing natural teeth, and survival rates of oral implants have been reported to be at least 90% at 10 years [39,40]. Rehabilitating edentulous alveolar ridges by dental implant are of potential interest in patients at high risk of IE, in whom therapeutic options are limited because of the contraindication of most conservative dental procedures. This treatment option is also subject to a strong demand by both patients and practitioners. This led the working group to analyse current knowledge on risk factors for implant failure, to propose an individualized approach in practice when discussing

implant placement in patients with valvular disease at high risk of IE.

Potential infectious risks related to dental implants

The placement of implants may be associated with mechanical, aesthetic or biological complications. The two main issues regarding infectious risk are immediate bacterial contamination at implant insertion and late failure with peri-implant disease, where bacterial community-induced inflammation causes progressive and irreversible disease in the hard and soft tissues surrounding the implant.

Infectious risk at implant insertion

Although bacteraemia has been shown to occur after invasive dental procedures, such as extraction and local anaesthesia, only two studies have been published on bacteraemia following implant placement [20,41]. The results underline that bacteraemia related to implant placement is low grade and less marked than for other invasive procedures and/or daily oral hygiene activities [10,42].

Bacteraemia could be further decreased by a prophylactic antiseptic mouth rinse with 0.2% chlorhexidine just before surgical intervention, as proposed previously by the British Society for Antimicrobial Chemotherapy [3].

Late failure with peri-implant disease

Peri-implantitis is an infectious disease associated with bone loss around the implant, combined with bleeding on probing and abnormal probing depth (Fig. 4). Various rates have been reported, but recent reliable estimations suggest that this complication occurs in approximately 10% of implants [43].

This bacterial disease, which can occur up to 10 years after implant placement, can sometimes lead to the removal of implants. To date, there are no specific recommendations for the treatment of peri-implantitis. It is therefore crucial, particularly in patients at high risk of IE, to identify and assess all risk factors for peri-implantitis that represent a possible cause of bacterial contamination.

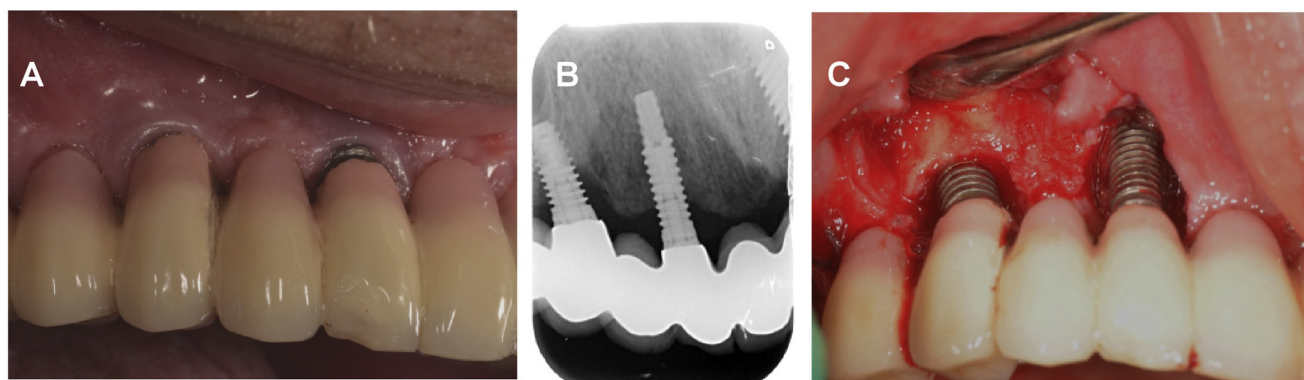


Figure 4. Peri-implantitis. A. Clinical view. B. Periapical radiography showing low osseous density around the mesial implant, and peri-implant bone loss involving 50% of the distal implant length. C. View of the osseous defects after surgical debridement.

Despite pathogenic similarities between periodontal diseases around natural teeth and peri-implantitis around dental implants, the vascular anatomical environment is different, inducing crucial clinical discrepancies. Periodontal tissues are richly vascularized, and represent an effective first-line defence mechanism against periopathogens, while the corresponding peri-implant tissue is much less vascularized because of the absence of periodontal ligament, making it more vulnerable to bacterial contamination.

Finally, if dental implant placement performed under strict aseptic conditions induces low-grade bacteraemia, the maintenance of oral health around implants is mandatory to decrease the risk of infections in patients at risk of IE.

Factors influencing patient susceptibility to peri-implant infection and implant failure

Cardiovascular risk factors and general diseases

Smoking

The results in the literature regarding the effects of smoking on implant complications are heterogeneous regarding definitions of smoking, duration and cumulative quantity, but there is now strong evidence to link smoking and risk of implant failure. Recent systematic reviews and meta-analyses [44,45] show that implant failure (loss of implant) and risk of local infection are twice as high in smokers compared with non-smokers. Given the increased risk of infection in patients at high risk of IE, the working group suggests avoiding implant therapy in active smokers, regardless of the number of cigarettes per day, and in former smokers who stopped less than 2 years previously.

Diabetes

The association between uncontrolled diabetes and periodontal disease is now well established. Severe periodontitis has a deleterious effect on glycaemic control in diabetic patients. The link between peri-implantitis and/or bone loss and uncontrolled diabetes is suggested in the literature [46]. However, a recent meta-analysis did not show any difference in implant success rate between well-stabilized diabetic patients and patients with uncontrolled diabetes [47].

Given the tight links between periodontitis and diabetes, and other pathogenic similarities between periodontitis

and peri-implantitis, the working group suggests avoiding implant therapy in patients at high risk of IE with uncontrolled diabetes (glycated haemoglobin [HbA1C] > 7%).

Corticosteroids and immunosuppressive therapies

Despite the number of patients treated with immunosuppressive therapy, a possible increase in infectious complications after implant surgery has not been established in the literature. The group cannot propose a recommendation to restrict the indication of implants in patients at high risk of IE who are treated with immunosuppressive therapy.

Local factors influencing the incidence of peri-implantitis and infection

Oral hygiene

It is unanimously recognized that oral hygiene is a crucial risk factor related to gingival, periodontal and peri-implant infectious diseases.

Experimental studies on healthy subjects with dental implants emphasize that the lack of oral hygiene induces gingival inflammation, and has a more important impact on the peri-implant tissue than on the gingiva surrounding natural teeth [48]. Recent published data also show a link between poor oral hygiene, the incidence of peri-implantitis and peri-implant bone loss [49]. Moreover, Lockhart et al. have also pointed out that poor oral hygiene is associated with an increased risk of developing bacteraemia, which could cause IE [50].

The working group proposes restricting the placement of dental implants to compliant patients for whom meticulous oral hygiene is checked and plaque control level is assessed regularly (twice a year).

History of periodontitis

Patients with a history of periodontitis (indicating an altered immune inflammatory response to oral bacteria challenge) or residual periodontal pockets ≥ 5 mm have a higher probability of developing peri-implantitis, marginal bone loss around implants and, ultimately, implant failure (Fig. 5) [51].

The working group proposes restricting the placement of dental implants to patients with no active periodontitis, and in whom the disease has been controlled for at least 1 year. It is possible that in the near future, identification of genetic

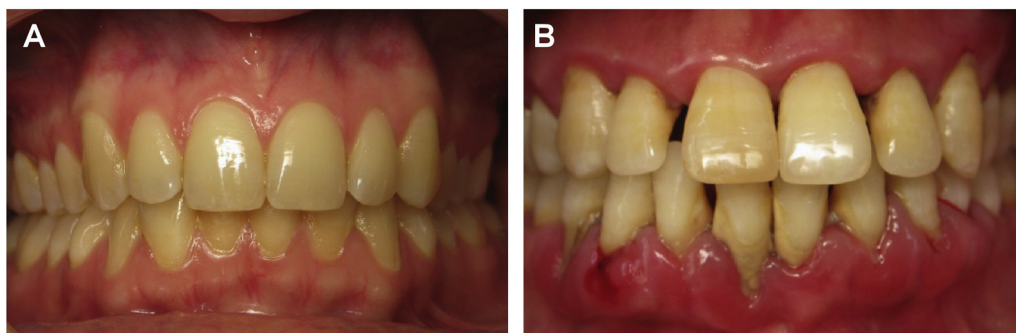

Figure 5. Clinical views illustrating (A) a healthy periodontium and (B) chronic periodontal disease. Periodontal disease is characterized by severe gingival inflammation in the mandibular arch, with spontaneous bleeding, marginal recessions exposing dental roots and dental migration. Calculus deposits are apparent along the gingival margin, enhancing the bacterial challenge against the periodontal tissues.

polymorphisms may help to identify patients at high risk of active periodontitis.

Maintenance therapy for the prevention of peri-implant disease

The pathophysiological similarities between peri-implantitis and periodontitis, and the increasing evidence for a positive effect of maintenance therapy in preventing tooth loss, have led to an evaluation of the impact of supportive maintenance therapy to prevent peri-implant disease. Recent studies showed that a strict maintenance programme after placement of implants is crucial to prevent biological and infectious complications related to implants [52,53]. Strict adherence to oral hygiene procedures, with visits to a specialist every 6 months, is recommended for maintenance.

These findings underline that oral health and supportive maintenance are key factors for the prevention of dental implant complications. Patient adherence to the treatment should be assessed.

The working group proposes that implant therapy in patients at high risk of IE requires complete periodontal examination to assess the absence of active periodontal disease and residual pockets. Dental implant success requires the initiation of long-term post-treatment twice-a-year recall programmes. The compliance of patients at high risk of IE should be carefully assessed before implant surgery.

Risk factors related to heart disease

Cardiac conditions at the highest risk of IE do not all carry the same risk of IE (Table 1). Patients with previous IE have a risk of annual recurrence estimated at 20 to 60 per 1000 [29,30], while the incidence of IE is markedly lower in patients with a heart valve prosthesis, estimated at 3 to 12 per 1000 patient-years [5,54].

Therefore, the working group proposes to contraindicate dental implants in patients with a previous episode of IE. In other high-risk conditions (any prosthetic valve and certain CHDs), there is no evidence to systematically contraindicate oral implantology.

Another factor to consider is anticoagulant therapy for patients with a mechanical valve prosthesis. These patients, under lifelong anticoagulant therapy, are at increased risk of bleeding, which should be taken into account for implant surgeries. In agreement with the French guidelines [32], only

dental procedures with a low bleeding risk are allowed with the continuation of oral anticoagulant therapy, i.e. placement of dental implant without bone apposition techniques (sinus elevation, bone graft, etc.) [55].

Risk factors related to surgical conditions and implant characteristics

Surgical environment conditions

In addition to patient factors that affect the risk of biological complications during or after implant placement, several factors related to surgical technique should be considered. Conditions and constraints in terms of the technical environment required for dental implants were proposed in France by the Haute Autorité de santé in 2008 [56].

The operating room should be "either specific to this type of intervention or adapted if the dental office meets the criteria in terms of asepsis". Implantology practice requires the use of two types of water (filtered and sterile water). The practitioner should be trained in these procedures, which require special training courses. The intervention must be as short as possible to reduce the risk of bacterial contamination. The patient should also be prepared by the medical team according to a strict protocol.

In high-risk patients, a single dose of antibiotic is indicated 1 hour before implant surgery, consistent with guidelines from the ESC and the USA [5,37]. Certain studies suggest a benefit of antibiotic prophylaxis before implant placement in the general population, but there is no evidence to recommend it in patients who are not at high risk of IE, in accordance with ANSM recommendations [28,57].

Choice of implants

The challenge of implantologists is to facilitate early osteointegration of the dental implant and subsequent loading protocols, and to ensure long-term bone-to-implant contact without substantial marginal bone loss and infectious complications. These issues have led to considerable research into the development of different implant designs and surface characteristics [58].

Recently, experimental and clinical studies have assessed the possible influence of the implant surface, particularly roughness, on the incidence of peri-implantitis. The results are contradictory, but the risk of developing early

peri-implantitis seems higher for rough surfaces. It has been shown that roughness is a determining factor in the increase of bacterial adhesion to the implant. Consequently, to limit bacterial colonization of the implant surface, and thereby the risk of peri-implant infection, the working group proposes choosing smooth implants for patients at high risk of IE. Regarding the length of the implants, the working group suggests using implants that do not exceed 10 mm, to facilitate removal in case of severe infection [58,59].

The occurrence of biological complications of implant placement also depends on other factors related to implant technique and implant characteristics. These factors should be carefully considered and discussed by dentists as possible secondary sources of infection for patients at high risk of IE. Examples of these factors are: the type of the prosthetic supra structure; immediate implant placement after extraction; the location of implants; the delay in implant placement after dental extraction; and the delay in implant loading after surgical placement.

Proposals for the use of implants in patients at high risk of IE

For patients with previous IE, the opinion of the study group is to maintain the contraindication of oral implantology (whatever the identified bacteria), given the particularly high risk of IE and the presence of probable host susceptibility factors involved in IE.

After valvular surgery, it is advised to wait at least 3 months before considering implant placement.

Dental implants can be used in other patients at high risk of IE, in accordance with the 2015 ESC guidelines [5]: patients with any prosthetic valve, including a transcatheter valve, or those in whom any prosthetic material was used for cardiac valve repair, at least 3 months after implantation; and patients with CHD and those with CHD who have post-operative palliative shunts, conduits or other prostheses.

Implant placement can be considered in these patients only under certain local and systemic strict conditions, after analysing numerous factors (general factors, local factors, technical environment and choice of implant).

Conclusions

Evolutions in the epidemiology and knowledge of the pathophysiology of IE, combined with advances in oral imaging and surgery techniques, now allow an individualized approach to the diagnosis and treatment of diseases in patients with heart valve diseases. The main consequence is the decrease of the number of contraindicated dental procedures. Conservative dental procedures can be performed before elective valvular interventions and during follow-up, even in patients at high risk of IE. Implant placement is no longer contraindicated in patients at high risk of IE, but the decision should take into account general and local factors associated with a risk of infectious complications and implant failure. A specific approach is proposed in patients with acute IE. Patients with previous IE are at particularly high risk of IE recurrence, and should not be considered as candidates for implant placement. In addition to

patient information, close collaboration is needed between odontologists, cardiologists and cardiac surgeons to improve evaluation of oral health, follow-up and the choice of dental procedures in patients with heart valve diseases.

Sources of funding

None.

Disclosure of interest

The authors declare that they have no competing interest.

References

- [1] Prophylaxie de l'endocardite infectieuse. Révision de la conférence de consensus de mars 1992. Recommandations 2002. *Med Mal Infect* 2002;32:542–52.
- [2] Baddour LM, Wilson WR, Bayer AS, et al. Infective endocarditis in adults: diagnosis, antimicrobial therapy, and management of complications: a scientific statement for healthcare professionals from the American Heart Association. *Circulation* 2015;132:1435–86.
- [3] Gould FK, Elliott TS, Fowleraker J, et al. Guidelines for the prevention of endocarditis: report of the working party of the British society for antimicrobial chemotherapy. *J Antimicrob Chemother* 2006;57:1035–42.
- [4] Habib G, Hoen B, Tornos P, et al. Guidelines on the prevention, diagnosis, and treatment of infective endocarditis (new version 2009): the task force on the prevention, diagnosis, and treatment of infective endocarditis of the European Society of Cardiology (ESC). Endorsed by the European society of clinical microbiology and infectious diseases (ESCMID) and the International society of chemotherapy (ISC) for infection and cancer. *Eur Heart J* 2009;30:2369–413.
- [5] Habib G, Lancellotti P, Antunes MJ, et al. 2015 ESC guidelines for the management of infective endocarditis: the task force for the management of infective endocarditis of the European society of cardiology (ESC). Endorsed by: European association for cardiothoracic surgery (EACTS), the European association of nuclear medicine (EANM). *Eur Heart J* 2015;36:3075–128.
- [6] National institute for health and clinical excellence. Prophylaxis against infective endocarditis: antimicrobial prophylaxis against infective endocarditis in adults and children undergoing interventional procedures (CG64); 2008 [Available at: <https://www.nice.org.uk/guidance/cg64>, accessed date: 10 November 2016].
- [7] Wilson W, Taubert KA, Gewitz M, et al. Prevention of infective endocarditis: guidelines from the American Heart Association: a guideline from the American Heart Association Rheumatic Fever, Endocarditis, and Kawasaki Disease Committee, Council on Cardiovascular Disease in the Young, and the Council on Clinical Cardiology, Council on Cardiovascular Surgery and Anesthesia, and the Quality of Care and Outcomes Research Interdisciplinary Working Group. *Circulation* 2007;116:1736–54.
- [8] Selton-Suty C, Celard M, Le Moing V, et al. Preeminence of *Staphylococcus aureus* in infective endocarditis: a 1-year population-based survey. *Clin Infect Dis* 2012;54:1230–9.
- [9] Duval X, Delahaye F, Alla F, et al. Temporal trends in infective endocarditis in the context of prophylaxis guideline

- modifications: three successive population-based surveys. *J Am Coll Cardiol* 2012;59:1968–76.
- [10] Lockhart PB, Brennan MT, Sasser HC, Fox PC, Paster BJ, Bahrani-Mougeot FK. Bacteremia associated with toothbrushing and dental extraction. *Circulation* 2008;117:3118–25.
- [11] Veloso TR, Amiguet M, Rousson V, et al. Induction of experimental endocarditis by continuous low-grade bacteremia mimicking spontaneous bacteremia in humans. *Infect Immun* 2011;79:2006–11.
- [12] French society of oral surgery. Management of oral-dental foci of infection; 2012 [Available at: http://www.societechirorale.com/documents/Recommandations/foyers_infectieux_argument-EN.pdf, accessed date: 10 November 2016].
- [13] Abella F, Patel S, Duran-Sindreu F, Mercade M, Bueno R, Roig M. An evaluation of the periapical status of teeth with necrotic pulps using periapical radiography and cone-beam computed tomography. *Int Endod J* 2014;47:387–96.
- [14] Almeida-Barros RQ, Abilio VM, Yamamoto AT, Melo DP, Godoy GP, Bento PM. Digital panoramic radiography versus cone beam computed tomography in the delineation of maxillo-mandibular tumors. *Gen Dent* 2015;63:e5–10.
- [15] Estrela C, Bueno MR, Leles CR, Azevedo B, Azevedo JR. Accuracy of cone beam computed tomography and panoramic and periapical radiography for detection of apical periodontitis. *J Endod* 2008;34:273–9.
- [16] Kaplan EL, Anderson RC. Infective endocarditis after use of dental irrigation device. *Lancet* 1977;2:610.
- [17] Simmons NA, Ball AP, Cawson RA, et al. Antibiotic prophylaxis and infective endocarditis. *Lancet* 1992;339:1292–3.
- [18] Dajani AS, Taubert KA, Wilson W, et al. Prevention of bacterial endocarditis. Recommendations by the American Heart Association. *JAMA* 1997;277:1794–801.
- [19] Barbosa M, Prada-Lopez I, Alvarez M, Amaral B, de los Angeles CD, Tomas I. Post-tooth extraction bacteraemia: a randomized clinical trial on the efficacy of chlorhexidine prophylaxis. *Plos One* 2015;10:e0124249.
- [20] Pineiro A, Tomas I, Blanco J, Alvarez M, Seoane J, Diz P. Bacteraemia following dental implants' placement. *Clin Oral Implants Res* 2010;21:913–8.
- [21] Ugwumba CU, Adeyemo WL, Odeniyi OM, Arotiba GT, Ogunsofa FT. Preoperative administration of 0.2% chlorhexidine mouthrinse reduces the risk of bacteraemia associated with intra-alveolar tooth extraction. *J Craniomaxillofac Surg* 2014;42:1783–8.
- [22] Klompas M, Speck K, Howell MD, Greene LR, Berenholtz SM. Reappraisal of routine oral care with chlorhexidine gluconate for patients receiving mechanical ventilation: systematic review and meta-analysis. *JAMA Intern Med* 2014;174:751–61.
- [23] Li L, Ai Z, Li L, Zheng X, Jie L. Can routine oral care with antiseptics prevent ventilator-associated pneumonia in patients receiving mechanical ventilation? An update meta-analysis from 17 randomized controlled trials. *Int J Clin Exp Med* 2015;8:1645–57.
- [24] Shi Z, Xie H, Wang P, et al. Oral hygiene care for critically ill patients to prevent ventilator-associated pneumonia. *Cochrane Database Syst Rev* 2013:CD008367.
- [25] Chen SJ, Liu CJ, Chao TF, et al. Dental scaling and risk reduction in infective endocarditis: a nationwide population-based case-control study. *Can J Cardiol* 2013;29:429–33.
- [26] Tai TW, Lin TC, Ho CJ, Kao Yang YH, Yang CY. Frequent dental scaling is associated with a reduced risk of periprosthetic infection following total knee arthroplasty: a nationwide population-based nested case-control study. *Plos One* 2016;11:e0158096.
- [27] Gupta N, Pal M, Rawat S, et al. Radiation-induced dental caries, prevention and treatment – A systematic review. *Natl J Maxillofac Surg* 2015;6:160–6.
- [28] ANSM. Prescription des antibiotiques en pratique bucco-dentaire; 2011 [Available at: <http://ansm.sante.fr/var/ansm.site/storage/original/application/9d56ce8171a4a370b3db47e702eab17f.pdf>, accessed date: 10 November 2016].
- [29] Fernandez-Hidalgo N, Almirante B, Tornos P, et al. Immediate and long-term outcome of left-sided infective endocarditis. A 12-year prospective study from a contemporary cohort in a referral hospital. *Clin Microbiol Infect* 2012;18:E522–30.
- [30] Thuny F, Giorgi R, Habachi R, et al. Excess mortality and morbidity in patients surviving infective endocarditis. *Am Heart J* 2012;164:94–101.
- [31] Tornos P, lung B, Permyner-Miralda G, et al. Infective endocarditis in Europe: lessons from the Euro heart survey. *Heart* 2005;91:571–5.
- [32] Société française de chirurgie orale. Gestion périopératoire des patients traités par antithrombotiques en chirurgie orale; 2015 [Available at: http://societechirorale.com/documents/Recommandations/recommandations_festioin_peri_operatoire_2015_court.pdf, accessed date: 10 November 2016].
- [33] Vahanian A, Alfieri O, Andreotti F, et al. Guidelines on the management of valvular heart disease (version 2012). *Eur Heart J* 2012;33:2451–96.
- [34] Reis LC, Rocas IN, Siqueira Jr JF, et al. Bacteremia after endodontic procedures in patients with heart disease: culture and molecular analyses. *J Endod* 2016;42:1181–5.
- [35] Venskutonis T, Plotino G, Tocci L, Gambarini G, Maminkas J, Juodzbaly G. Periapical and endodontic status scale based on periapical bone lesions and endodontic treatment quality evaluation using cone-beam computed tomography. *J Endod* 2015;41:190–6.
- [36] Weissman J, Johnson JD, Anderson M, et al. Association between the presence of apical periodontitis and clinical symptoms in endodontic patients using cone-beam computed tomography and periapical radiographs. *J Endod* 2015;41:1824–9.
- [37] Nishimura RA, Otto CM, Bonow RO, et al. 2014 AHA/ACC guideline for the management of patients with valvular heart disease: a report of the American college of cardiology/American heart association task force on practice guidelines. *J Am Coll Cardiol* 2014;63:e57–185.
- [38] Findler M, Chackartchi T, Regev E. Dental implants in patients at high risk for infective endocarditis: a preliminary study. *Int J Oral Maxillofac Surg* 2014;43:1282–5.
- [39] Pjetursson BE, Thoma D, Jung R, Zwahlen M, Zembic A. A systematic review of the survival and complication rates of implant-supported fixed dental prostheses (FDPs) after a mean observation period of at least 5 years. *Clin Oral Implants Res* 2012;23(Suppl. 6):22–38.
- [40] van Velzen FJ, Ofec R, Schulten EA, Ten Bruggenkate CM. 10-year survival rate and the incidence of peri-implant disease of 374 titanium dental implants with a SLA surface: a prospective cohort study in 177 fully and partially edentulous patients. *Clin Oral Implants Res* 2015;26:1121–8.
- [41] Bolukbasi N, Ozdemir T, Oksuz L, Gurler N. Bacteremia following dental implant surgery: preliminary results. *Med Oral Patol Oral Cir Bucal* 2012;17:e69–75.
- [42] Zhang W, Daly CG, Mitchell D, Curtis B. Incidence and magnitude of bacteraemia caused by flossing and by scaling and root planing. *J Clin Periodontol* 2013;40:41–52.
- [43] Atieh MA, Alsabeeha NH, Faggion Jr CM, Duncan WJ. The frequency of peri-implant diseases: a systematic review and meta-analysis. *J Periodontol* 2013;84:1586–98.
- [44] Chrcanovic BR, Albrektsson T, Wennerberg A. Smoking and dental implants: a systematic review and meta-analysis. *J Dent* 2015;43:487–98.

- [45] Renvert S, Quirynen M. Risk indicators for peri-implantitis. A narrative review. *Clin Oral Implants Res* 2015;26(Suppl. 11):15–44.
- [46] Ferreira SD, Silva GL, Cortelli JR, Costa JE, Costa FO. Prevalence and risk variables for peri-implant disease in Brazilian subjects. *J Clin Periodontol* 2006;33:929–35.
- [47] Shi Q, Xu J, Huo N, Cai C, Liu H. Does a higher glycemic level lead to a higher rate of dental implant failure? A meta-analysis. *J Am Dent Assoc* 2016;147:875–81.
- [48] Salvi GE, Aglietta M, Eick S, Sculean A, Lang NP, Ramseier CA. Reversibility of experimental peri-implant mucositis compared with experimental gingivitis in humans. *Clin Oral Implants Res* 2012;23:182–90.
- [49] Koller CD, Pereira-Cenci T, Boscatto N. Parameters associated with marginal bone loss around implant after prosthetic loading. *Braz Dent J* 2016;27:292–7.
- [50] Lockhart PB, Brennan MT, Thornhill M, et al. Poor oral hygiene as a risk factor for infective endocarditis-related bacteremia. *J Am Dent Assoc* 2009;140:1238–44.
- [51] Vervaeke S, Collaert B, Cosyn J, De Bruyn H. A 9-year prospective case series using multivariate analyses to identify predictors of early and late peri-implant bone loss. *Clin Implant Dent Relat Res* 2016;18:30–9.
- [52] Monje A, Alcoforado G, Padiá-Molina M, Suarez F, Lin GH, Wang HL. Generalized aggressive periodontitis as a risk factor for dental implant failure: a systematic review and meta-analysis. *J Periodontol* 2014;85:1398–407.
- [53] Monje A, Aranda L, Diaz KT, et al. Impact of maintenance therapy for the prevention of peri-implant diseases: a systematic review and meta-analysis. *J Dent Res* 2016;95:372–9.
- [54] Wang A, Pappas P, Anstrom KJ, et al. The use and effect of surgical therapy for prosthetic valve infective endocarditis: a propensity analysis of a multicenter, international cohort. *Am Heart J* 2005;150:1086–91.
- [55] Poli PP, Beretta M, Grossi GB, Maiorana C. Risk indicators related to peri-implant disease: an observational retrospective cohort study. *J Periodontal Implant Sci* 2016;46:266–76.
- [56] Haute Autorité de santé. Conditions de réalisation des actes d'implantologie orale : environnement technique; 2008 [Available at: http://www.has-sante.fr/portail/jcms/c_679792/fr/conditions-de-realisation-des-actes-d-implantologie-orale-environnement-technique].
- [57] Veitz-Keenan A, Keenan JR. Antibiotic use at dental implant placement. *Evid Based Dent* 2015;16:50–1.
- [58] Smeets R, Stadlinger B, Schwarz F, et al. Impact of dental implant surface modifications on osseointegration. *Biomed Res Int* 2016;2016:6285620.
- [59] Yeo IS, Kim HY, Lim KS, Han JS. Implant surface factors and bacterial adhesion: a review of the literature. *Int J Artif Organs* 2012;35:762–72.